



PARTIAL STERNAL RESECTIONS IN PRIMARY AND METASTATIC TUMORS WITH NON RIGID RECONSTRUCTION OF CHEST WALL

Dr. Cherian Mathew	Chief Surgeon, Dept. Of General Surgery, Muthoot Hospital, College Road, Kozhencherry, 689641
Dr. Harish Kumar H	Consultant Surgical Oncologist, Muthoot Hospital, College Road, Kozhencherry, 689641
Dr. Sai Kiran	Consultant Surgeon, Dept. Of General Surgery, Muthoot Hospital, College Road, Kozhencherry, 689641
Dr. Mary Treasa Pouline	Resident, Dept. Of General Surgery, Muthoot Hospital, College Road, Kozhencherry, 689641

ABSTRACT

Various approaches have been described for thyroidectomy in the literature. Of late, minimal access approach has been explored through different routes like axillary, breast or anterior chest, intraoral approaches. Advantages being avoidance of visible scar in the neck with excellent cosmetic results, good intraoperative visualization, thereby reducing risk of intraoperative complications, and early postoperative recovery. With this background, we hereby share our early experience with endoscopic thyroidectomy.

KEYWORD

Thyroidectomy; Endoscopic; Benign; Cosmesis;

ARTICLE HISTORY

Submitted: 07-08-2017

Accepted: 29-08-2017

Published: 10-11-2017

*Corresponding Author Dr. Harish Kumar H

Consultant Surgical Oncologist, Muthoot Hospital, College Road, Kozhencherry, 689641
harishkumarh1983@gmail.com

INTRODUCTION:

Conventional or open thyroidectomy was the most commonly practiced approach for thyroid disorders which was treated surgically. With time, minimal access approach was explored. Minimal invasive video assisted thyroidectomy (MIVAT), was the earliest minimal access approach being explored which was described for the first time by Miccoli et al [1]. Ikeda et al. described endoscopic approach via axillary incision [2]. Good cosmesis, decreased postoperative pain, and shortening of inpatient period, decreased postoperative complication rates are some of the described advantages of minimal access approach.

Thyroid nodules lesser than 3 cm in diameter, thyroid glands with a volume less than 25 mL, absence of the thyroid gland fixation (thyroiditis, history of neck irradiation or previous neck surgery and extrathyroid cancer spread), follicular

tumor or "low risk" papillary carcinoma, and RET gene mutation carriers-elective thyroidectomy are some of the important criteria laid down by Miccoli for minimally invasive video assisted thyroidectomy [3]. Development in robotic surgery technology facilitated introduction of alternate approaches like transoral video-assisted thyroidectomy (TOVAT) or retroauricular approach (RA) [4,5]. With large proportion of patients being young females, minimally invasive approach remains as an appealing technique with various advantages described.

MATERIALS AND METHODS:

It was a retrospective analysis of cases done over period of 2 years with literature review done using databases pubmed, google scholar and research gate with terms using endoscopic, laparoscopic thyroidectomy.

Clinical characteristics and details of surgical treatment:

Parameters	Case 1	Case 2	Case 3	Case 4	Case 5
Age (years)	37	46	42	26	35
Sex	F	F	F	F	M
Nodule size (Ultrasound)	2x2.2 cm	3.9x2.4 cm	2.3x1.7cm(left lobe) 3.3x1.8cm(right lobe)	3.2X2.5	2.7X2.5
FNAC	Benign cystic lesion	Nodular goitre	Adenomatous goitre	Nodular goitre	Nodular goitre
Site	Left lobe	Right lobe	Both lobes	Right lobe	Right lobe
Duration of procedure	2hrs, 30 min	2hrs, 45 min	4hrs 30 min	2hrs, 10 min	3hrs
Estimated blood loss	50ml	50 ml	150 ml	80ml	60ml
Final HPR	Nodular goitre	Nodular goiter with degenerative changes	Papillary carcinoma	Nodular goitre	Nodular goitre

Hospital stay	3 days	3 days	3 days	3 days	3 days
Recurrent laryngeal nerve injury	NIL	NIL	NIL	NIL	NIL
Hypoparathyroidism	n/a	n/a	NIL	n/a	n/a
Hematoma/wound infection	NIL	NIL	NIL	NIL	NIL
VAS pain score	2	2	3	2	3

HPR- Histopathology report

n/a – not applicable

VAS- Visual analog score

CASE SERIES:

Case 1:

37 year old female presented with nodule in left lobe of thyroid since one month. Thyroid function tests and other blood parameters were normal. Ultrasound neck was suggestive of nodule arising from left lobe of thyroid measuring 2x2.2cm. Fine needle aspiration cytology of the nodule revealed benign cystic lesion. Endoscopic left hemithyroidectomy was done. Final histopathology was suggestive of benign tumor. Duration of surgery was 2 hours and 30 minutes. Blood loss was around 50 ml. No significant postoperative complications noted. Postoperative pain score was 2. Patient was discharged on postoperative day 3. On follow up after one week, patient was better.

Case 2:

46 year old female presented with nodule in right lobe of thyroid since two months. Thyroid function tests and other blood investigations were within normal limits. Ultrasound neck was suggestive of nodule arising from right lobe of thyroid measuring 3.9x2.4cm. Fine needle aspiration cytology of the nodule revealed nodular goiter. Endoscopic right hemithyroidectomy was done. Duration of surgery was 2 hours and 45 minutes. Blood loss was around 50 ml. No significant postoperative complications noted. Postoperative pain score was 2. Patient was discharged on postoperative day 3. On follow up after two weeks, no significant complaints noted.

Case 3:

42 year old female presented with nodule in both lobes of thyroid since 15 days. Thyroid function tests and other blood investigations were within normal limits. Ultrasound neck was suggestive of nodule arising from right lobe of thyroid measuring 3.3x1.8cm and nodule measuring 2.3x1.7 cm from left lobe of thyroid. Fine needle aspiration cytology of the nodule revealed adenomatous goiter. Endoscopic total hemithyroidectomy was done. Final histopathology was suggestive of papillary carcinoma. There was no evidence of significant lymph nodes in level 6 either by imaging or intraoperatively. Duration of surgery was 4 hours and 30 minutes. Blood loss was around 150 ml. No significant postoperative complications noted. Postoperative pain score was 3. Patient was discharged on postoperative day 3. On follow up after two weeks, no significant complaints noted. Patient was referred to nuclear medicine department for radioactive iodine scan.

Case 4:

26 year old female presented with nodule in right lobe of thyroid since two months. Thyroid function tests and other blood investigations were within normal limits. Ultrasound neck was suggestive of nodule arising from right lobe of thyroid measuring 3.2x2.5cm. Fine needle aspiration cytology of the nodule revealed nodular goiter. Endoscopic right hemithyroidectomy was done. Duration of surgery was 2 hours and 10 minutes. Blood loss was around 80 ml. No significant postoperative complications noted. Postoperative pain score was 2. Final histopathology report was suggestive of nodular goiter. Patient was discharged on postoperative day 3. On follow up after two weeks, no significant complaints noted.

Case 5:

37 year old female presented with nodule in right lobe of

thyroid since two months. Thyroid function tests and other blood investigations were within normal limits. Ultrasound neck was suggestive of nodule arising from right lobe of thyroid measuring 2.7x2.5cm. Fine needle aspiration cytology of the nodule revealed nodular goiter. Endoscopic right hemithyroidectomy was done. Duration of surgery was 3 hours. Blood loss was around 60 ml. No significant postoperative complications noted. Postoperative pain score was 2. Patient was discharged on postoperative day 3. On follow up after two weeks, no significant complaints noted.

Operative technique:

Endoscopic left hemithyroidectomy .

Under General anaesthesia, patient in supine position, parts painted and draped. 10mm camera port created above left breast 3cm from anterior axillary line and trochar introduced and plane created above pectoral fascia. 2x 5mm working ports created in left breast at 1 O' clock position and left anterior axillary fold. Zero Degree camera port introduced and subplatysmal plane created. Dissection proceeded upto exposure of sternocleidomastoid, strap muscles and crosses the midline. Strap muscles separated by splitting in the midline and pretracheal fascia exposed and incised and thyroid gland exposed. Left inferior pedicle divided using harmonic scalpel. Middle thyroid vein divided. Upper pole identified and superior pedicle also divided with Harmonic scalpel. Thyroid retracted medially and attachment to trachea is divided upto the midline. Isthmus divided close to the right lobe using harmonic scalpel. Left lobe of thyroid and isthmus delivered in endoscopic retrieval bag. Hemostasis achieved. 18F romovac suction drain inserted and fixed. 10mm port closed with silk and 5 mm ports closed with dermabond.

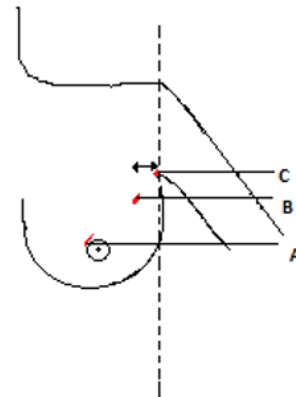


Figure 1; Port placements for endoscopic left hemithyroidectomy.

- A: 5mm working port at 11'O' clock position in periareolar region
- B: Camera port placed at about 2 cm from anterior axillary line midway between two working ports
- C: Second working port placed just anterior to deltopectoral groove at level of anterior axillary line as shown in figure 1.

For, right hemithyroidectomy, Similar port placements and dissection techniques were followed on right side.

For total thyroidectomy, Thyroid was approached from both sides using both left and right sided ports, and port placements were similar as explained above.

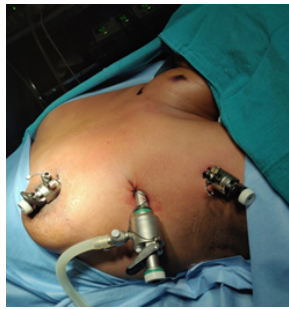Operative Photographs:

Figure 2: Port placement for left hemithyroidectomy

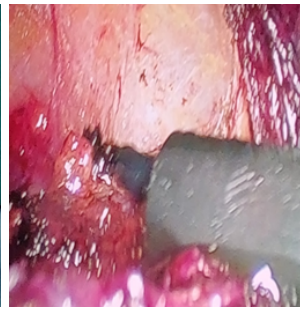


Figure 3: Raising sub platy small flap

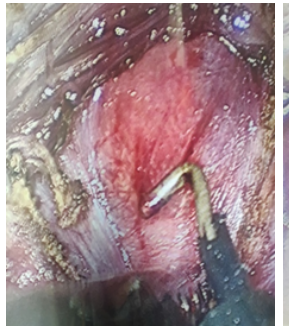


Figure 4: Exposure of anterior surface of thyroid



Figure 5: Dissection to expose upper pole

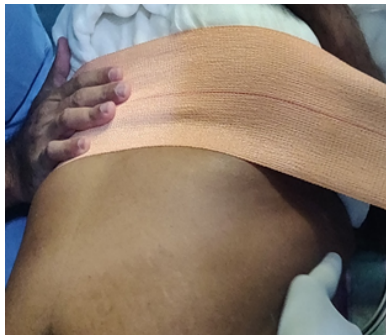

Figure 6: Pressure dressing to avoid subcutaneous emphysema.

DISCUSSION:

Any innovative method, be it surgical technique or access methods are acceptable only when it adds to safety, early post operative recovery, lesser complications and any other outcomes that are comparable to the standard method. In most of the situations, minimal access technique has shown such comparable results when matched with open technique. Thyroid surgery has revolutionized from Kocher's open method to Miccolis MIVAT (Minimal invasive video assisted thyroidectomy) having its own limitations. With time, different access methods have been explored with variable results.

According to the literature, Huscher has been credited to have performed the first endoscopic thyroidectomy [6]. Later, many surgeons have explored various access methods with or without CO₂ (Carbon dioxide) gas. El-Labban in his work using MIVAT method, has shown significant greater satisfaction with cosmetic outcome when compared to conventional method, and reduced pain score, but with greater operative time, and has also stated that, with more experience, operative time can be reduced. Thyroid nodules less than 5–6 cm in diameter, and differentiated thyroid carcinoma less than 3–4 cm [9,10]. Band-like contracture of the neck, anterior chest, and axillary area, probably due to fibrotic contracture of soft tissue and muscles are some of the complications described in literature with use of endoscopic

methods [11,12]. Robotic technology and endoscopic methods have been tried for Neck dissection as well [13,14,15].

Majority of the patients in our series were females and belonged to middle aged group. Benign tumors were the only cases included in our series. Size criteria on ultrasound ranged from as less as 2 cm to as high as 3.9 cm. Duration of the procedure were as less as 2 hours 10 mins for hemithyroidectomy to as high as 4 hours 30 minutes for total thyroidectomy. Blood loss ranged from 50–80 ml for hemithyroidectomy to 150 ml for total thyroidectomy. All patients were in euthyroid state. Hospital stay was for about 3 days. No evidence of recurrent laryngeal nerve palsy, hypoparathyroidism, wound infection or hematoma were noted in our series. Pain (Visual analog score) ranged from 2–3. Paolo Del Rio et al., in his series of 497 cases done over the period of 10 years, has reported that the indications were Thyroid volume <30 mL, Nodule <35 mm, Goiter, Hyperfunctioning thyroid, Follicular lesion, Low–intermediate risk carcinoma. Complication rate were definitive laryngeal nerve palsy 1.3%, Definitive hypoparathyroidism 2.2% and Postoperative bleeding was 1.6%. Postoperative pain score was 1.06±0.56 after 24 hours [16]. In another multiinstitutional study from north America done by David J. Terris et al, cases included were nodules less than 3 cm and without thyroiditis. 80% of cases were of benign nature. No evidence of definitive recurrent laryngeal nerve palsies, hypocalcemia or hematoma were seen except for transient vocal cord paresis and hypocalcemia in few cases. 30 degree camera was used for visualization of superior pole and recurrent laryngeal nerve unlike in our case [17].

Zdenjk Fik et al., in his comparative study of Minimally Invasive Video-Assisted versus Minimally Invasive Nonendoscopic Thyroidectomy has stated that the cases included in minimally invasive video assisted thyroidectomy, were those with nodule size ranging from 20 to 31 mm, and thyroid volume ranging from 12–19 mL. Duration of surgery ranged from 77 to 101 minutes for hemithyroidectomy. Blood loss ranged from 60 to 90 mL. Pain score was about 0–2.5 cases had transient hypocalcemia and 2 cases had postoperative bleeding. Inpatient stay was on an average 3 days [18]. In another case series, by Massimo Ruggieri et al., where gasless video assisted endoscopic thyroidectomy technique was used, has reported that, this technique was feasible even in thyroid volumes of up to 50 mL [19].

With this background, Endoscopic thyroidectomy option can be explored in majority of the benign thyroid conditions with various inclusion criteria mentioned above with acceptable complication rate, and good postoperative recovery and good cosmesis.

CONCLUSION:

With exception of few limitations, Endoscopic approach can be an excellent option for thyroidectomy, specially the benign ones. Routes may vary based on expertise of the surgeon, and personal preference. Further studies need to be conducted, specially to explore this viable option in malignant conditions.

REFERENCES:

1. Miccoli P, Berti P, Conte M, Bendinelli C, Marcocci C. Minimally invasive surgery for thyroid small nodules: preliminary report. *J Endocrinol Invest.* 1999; 22(11):849–851.
2. Y. Ikeda, H. Takami, M. Niimi, S. Kan, Y. Sasaki, and J. Takayama, "Endoscopic thyroidectomy by the axillary approach," *Surgical Endoscopy*, vol. 15, no. 11, pp. 1362–1364, 2001.
3. P. Miccoli, P. Berti, G. L. Frustaci, C. E. Ambrosini, and G. Materazzi, "Video-assisted thyroidectomy: indications

- and results," *Langenbeck's Archives of Surgery*, vol. 391, no. 2, pp.68–71,2006.
4. E.Karakas, T.Steinfeldt, A. Gockel et al., "Transoral thyroid and parathyroid surgery—development of a new transoral technique," *Surgery*, vol. 150, no. 1, pp. 108–115, 2011.
 5. H. M. Schardey, M. Barone, S. P'ortl, M. von Ahnen, T. von Ahnen, and S. Schopf, "Invisible scar endoscopic dorsal approach thyroidectomy: a clinical feasibility study," *World Journal of Surgery*, vol. 34, no. 12, pp. 2997–3006, 2010.
 6. Huscher CS, Chiodini S, Napolitano C, Recher A. Endoscopic right thyroid lobectomy. *Surg Endosc*. 1997 Aug;11(8):877.
 7. El-Labban GM. Minimally invasive video-assisted thyroidectomy versus conventional thyroidectomy: A single-blinded, randomized controlled clinical trial. *J Min Access Surg* 2009;5:97-102.
 8. Tae K et al. Robotic and Endoscopic Thyroid surgery: Evolution and advances.. *Clinical and Experimental Otorhinolaryngology* Vol. 12, No. 1: 1-11, February 2019
 9. Tae K, Ji YB, Jeong JH, Lee SH, Jeong MA, Park CW. Robotic thyroidectomy by a gasless unilateral axillo-breast or axillary approach: our early experiences. *Surg Endosc*. 2011 Jan;25(1):221-8.
 10. Tae K, Ji YB, Cho SH, Lee SH, Kim DS, Kim TW. Early surgical outcomes of robotic thyroidectomy by a gasless unilateral axillo-breast or axillary approach for papillary thyroid carcinoma: 2 years' experience. *Head Neck*. 2012 May;34(5):617-25
 11. Kwak DH, Kim WS, Kim HK, Bae TH. A band-like neck scar contracture after bilateral axillo-breast approach robotic thyroidectomy. *Arch Plast Surg*. 2016 Nov;43(6):614-5. 12. Kim JH, Park JW, Gong HS. Axillary web syndrome after transaxillary robotic thyroidectomy. *J Robot Surg*. 2014 Sep;8(3):281-3.
 13. Kang SW, Lee SH, Ryu HR, Lee KY, Jeong JJ, Nam KH, et al. Initial experience with robot-assisted modified radical neck dissection for the management of thyroid carcinoma with lateral neck node metastasis. *Surgery*. 2010 Dec;148(6):1214-21.
 14. Song CM, Ji YB, Sung ES, Kim DS, Koo HR, Tae K. Comparison of robotic versus conventional selective neck dissection and total thyroidectomy for papillary thyroid carcinoma. *Otolaryngol Head Neck Surg*. 2016 Jun;154(6):1005-13.
 15. Kim WS, Koh YW, Byeon HK, Park YM, Chung HJ, Kim ES, et al. Robot-assisted neck dissection via a transaxillary and retroauricular approach versus a conventional transcervical approach in papillary thyroid cancer with cervical lymph node metastases. *J Laparoendosc Adv Surg Tech A*. 2014 Jun;24(6):367-7
 16. Del Rio P, Viani L, Montana CM, Cozzani F, Sianesi M. Minimally invasive thyroidectomy: a ten years experience. *Gland Surg* 2016;5(3):295-299.
 17. Terris DJ, Angelos P, Steward DL, Simental AA. Minimally Invasive Video-Assisted Thyroidectomy: A Multi-institutional North American Experience. *Arch Otolaryngol Head Neck Surg*. 2008;134(1):81–84.
 18. Fik Z, Astl J, Záborský M, et al. Minimally invasive video-assisted versus minimally invasive nonendoscopic thyroidectomy. *Biomed Res Int*. 2014;
 19. Massimo Ruggieri, Andrea Straniero1, Mariapia Genderini , Massimino D'Armiento, Angela Fumarola, Pierpaolo Trimbol et al., .The size criteria in minimally invasive video-assisted Thyroidectomy. *BMC Surgery* 2007 7:2