



## PERIportal FIBROSIS AND CONTRACTED GALL BLADDER IN USG OF HEPATOBILIARY SYSTEM- AS A DIAGNOSTIC FACTOR AND THERAPEUTIC STRATEGY FOR BILIARY ATRESIA

<b>Dinesh Prasad Koirala</b>	Tribhuvan university Teaching Hospital Paediatric surgery Unit. Building H, kathmandu, Nepal
<b>Shafiqul Hoque</b>	Tribhuvan university Teaching Hospital Paediatric surgery Unit. Building H, kathmandu, Nepal
<b>A. K. M Zahid Hossain</b>	Tribhuvan university Teaching Hospital Paediatric surgery Unit. Building H, kathmandu, Nepal
<b>Humaira Islam</b>	Tribhuvan university Teaching Hospital Paediatric surgery Unit. Building H, kathmandu, Nepal

### ABSTRACT

This study aims to establish the ultrasonographic finding of periportal fibrosis and contracted gall bladder as diagnostic factor and therapeutic strategy for Biliary Atresia. Twenty five infants were taken into study from Jan 2014-March 2016. All the patients had undergone ultrasonography of whole abdomen. For assisting the diagnosis 20 children had HIDA scan and percutaneous liver biopsy. The diagnosis was supported by undergoing Kasai procedure in 18 children. It was further supported by histopathological report after Kasai procedure. The age of presentation varies from 45 days to 120 days. Most of the children had clinical presentation of Biliary Atresia i.e. persistent jaundice, acholic stool, and abdominal mass. For further diagnosis Ultrasonography of whole abdomen was done. USG finding in 19 patients revealed periportal fibrosis ranging from 15 x 9mm-20x12mm. In 17 patients the gall bladder was present which appeared to be irregularly contracted. In 4 patients sacculated well defined gall bladder was present. In three patients gall bladder was absent. Among 20 patients with HIDA Scan and percutaneous liver biopsy 18 patients revealed features of Biliary Atresia. Among 18 patients who had undergone Kasai procedure, 16 patients revealed absence of Biliary tract and contracted gall bladder. Two patients had common bile duct and normal looking gall bladder. The tissue from the extrabiliary tract on histopathology after Kasai procedure also revealed periportal fibrosis and chronic inflammatory cells. The findings in ultrasonography with periportal fibrosis and contracted gall bladder aid in early diagnosis and therapeutic strategy of Biliary Atresia specially in Indian subcontinent where all the people cannot afford the expensive investigations. However larger study is required to establish this relation provided USG features are carefully analysed by an experienced operator.

### KEYWORD

Ultrasonographic, Periportal, Histopathological

### ARTICLE HISTORY

Submitted: 10-05-2018

Accepted: 4-09-2018

Published: 10-09 2018

\*Corresponding Author Dinesh Prasad Koirala

koiraladinesh1@hotmail.com

### INTRODUCTION

Biliary Atresia is a congenital biliary disorder, commonly causing progressive and obstructive pathological changes in the intra-hepatic and extra-hepatic ducts secondary to inflammation and often causing progressive fibrosis and liver damage resulting in cirrhosis of liver and consequent liver failure. (Shi-Xing La, 2008)

It can be syndromic and non syndromic. Syndromic is also known as embryonic type occur during developmental insult in differentiation of hepatic diverticulum from the foregut of the embryo. Non syndromic is also known as perinatal type occurs due to biliary obstruction of extra hepatic Biliary tree. Several Viruses such as Reo virus, Rotavirus, CMV, Epstein Barr virus are considered to be culprit. (Hee-Jung, 2003)

It is thought to affect 1 in 10,000 -15000 new born infants. Male are preponderance. Those infants may be normal at birth. However symptoms develop after 2 weeks to 2 months of life. The common presentations are persistent progressive jaundice, acholic stool and hepatomegaly (Y, Weerakkody). Favorable outcome is achieved if Biliary Atresia can be diagnosed as early as possible. Jaundice free survival may be

achieved if hepatic portoenterostomy can be performed within 60 days of life. Thus early differentiation of Biliary Atresia from neonatal hepatitis or other cause of infantile cholestatic jaundice is very important.

Till today no single pre-operative investigation has come with certainty of diagnosis. So the evaluation of infants suspected of having Biliary Atresia has become challenging for physicians since many decades. Liver function assessment, HIDA scan, percutaneous needle liver biopsy and laparoscopic Color Doppler are thought to be useful, but their results are not individually diagnostic.

The evaluation of BA in the third world (developing countries) has become quite difficult due to limited resources i.e. socio economic status or unavailability of imaging facilities. It is well accepted that non invasive imaging tools like USG machine has the highest diagnostic accuracy since it avoids the unnecessary interventions. (Mittal, 2011)

The advantages of ultrasonography are its convenience, non-invasiveness and thinness of infant abdominal wall. The process can be repeated without adverse effect. (Shi-Xing La, 2008)

With advancement of high resolution detecting head, the sonogram becomes increasingly clear. However no general and unitive diagnostic criteria for Biliary Atresia are available at present. So this study was therefore done to outline the ultrasonic findings in infants with cholestatic jaundice suspected to have Biliary Atresia demonstrating periportal fibrosis and contracted gall bladder. Attempts were made to co-orelate these findings with HIDA scan, liver biopsy, operative findings and biopsy from surgery.

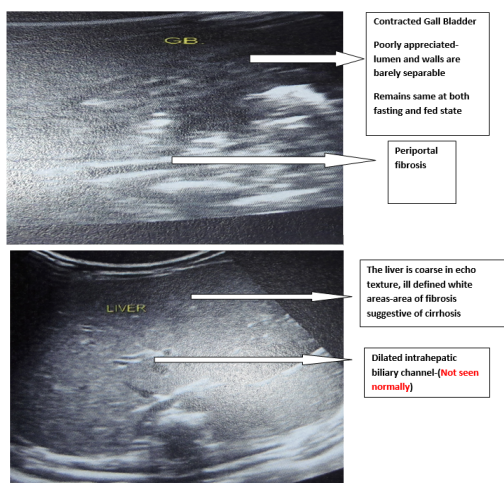
**METHODS AND MATERIALS**

Prospective, descriptive study of 25 consecutive persistently jaundiced infants was studied between Feb 2014 to March 2016 in Bangabhandhu sheikh Mujib medical university and some private clinics. All the infants were evaluated first by liver biochemistry assay especially bilirubin level –direct ,SGPT, alkaline phosphates, gamma GGT and coagulation profile, followed by HIDA scan and USG Guided liver biopsy. The infants had undergone Kasai procedure. The findings were evaluated preoperatively and histopathological report.

**USG**

All infants underwent a detailed US examination by experienced operator. Gall bladder cannot be assessed at well fed state. So, the infants were not breast feed for 4 hours before examination. None of the infants were sedated. The sonographic exam was performed by Machine GEVOLUTION E8 Expert with abdominal probe C1-D Probe ,2-5 MHZ, 11 L-D Probe 4-10 MHZ. The gall bladder was interrogated to lay its shape and regularity of its wall. An irregular wall and a distortion of the gall bladder was considered abnormal (Fig1) Gall bladder is poorly appreciated, lumen and walls are barely separable and the gall bladder remain same at both feeding and fasting state. The length of the gall bladder < 15 mm was considered contracted (Kimio et al, 2003).

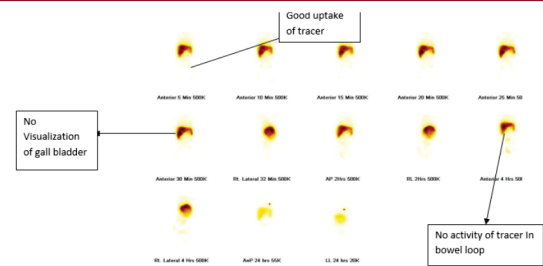
Extra hepatic bile ducts have most often become scarred cords of tissue which we have called as periportal fibrosis. These are the tissues that are presented anterior and posterior to porta hepatis.



**Fig 1: Scan of Hepatobiliary System**

**Percutaneous liver Biopsy:** It was done with paediatric size needle i.e. 1.6 mm internal diameter and 7 cm length. It revealed the features of cholestasis.

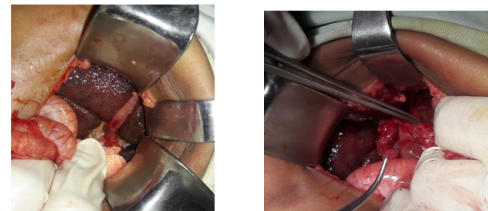
**HIDA scan** was done; Common findings in favor of Biliary Artesia-Neither gall bladder nor common bile duct was visualized upto 30 minutes images. Tracer activity within the bowel loop wasnot upto 4 hours.



**Fig 2: HIDA Scan**

**Laparotomy** was done;

Objective was to confirm the diagnosis by visualizing the presence of fibrotic cord in the region of porta hepatis and bile duct. The flow of bile was checked repeatedly by a normal saline soaked guaze piece for 5 mins. The cirrhotic change of liver, remnants of extrahepatic tissue and gall bladder was observed. Kasai (Portoenterostomy) procedure was carried out in 18 patients.



**Fig 3: Operative Picture a) showing Cirrhotic liver and contracted gall bladder. b) absence of extrahepatic tissue and presence of fibrotic tissue**

**Histopathology;** The tissue from periportal area, gall bladder and liver was sent for histopathology. Tissue from periportal area shows fibrosis and chronic inflammatory cells. Gall Bladder revealed mild fibrosis ad moderate infiltration of chronic inflammatory cells.

**Eligibility; Inclusion; Patient** with florid presentation of Biliary Artesia i.e. persistent jaundice, clay colored stool and abdominal mass

Patient who are willing to perform the investigations like USG of abdomen, HIDA scan, percutaneous liver biopsy Parent who have given consent for surgical intervention

**Exclusion:**

Patient not willing to participate in the study

**Operational definition;**

**Periportal fibrosis;** Extra hepatic bile ducts which have become scarred cords of tissue

**Contracted Gall Bladder;** The maximal gall bladder length is measured and the gall bladder shape is evaluated using a high frequency transducer.

When considering the gall bladder shape a discontinuous or absent mucosal lining and indistinct wall, and an irregular outer margin are regarded as abnormal i.e. lumen and walls are barely separable. The gall bladder was considered contracted when it was less than 1.5cm long, wasnot dectable or detectable but had no lumen. The gall bladder remain same in both fasting and feeding state.

**RESULTS;**

The age range of twenty five study subjects was within the mean of three Months (48 days – 5 months). More than half of them (68%) were less than 72 days old while remaining were more than 90days old. Majority of them were (60%) female with all of them presenting with persistent progressive jaundice, acholic stool and abdominal distension. The onset

of jaundice was less than 7 days in 52 % of cases and 7-21 days in 25% of the cases. However in 20 % of cases mother couldn't recall the exact timing of jaundice. USG findings in 19 patients revealed periportal fibrosis ranging from 15X09 mm-20x12 mm. In 6 patients no obvious fibrosis was seen. In 17 patients the gall bladder was present which appeared to be less than 1.5 mm contracted and no lumen were found. In 4 patients saccular well defined gall bladder was present and in four patient gall bladder was absent.

#### DISCUSSION:

The cause of Biliary Arteria is not well known yet. Unless the hepatic portoenterostomy is performed within first 60 days survival without jaundice and its consequences like cirrhosis portal hypertension, is not possible. Therefore it is very important to promptly diagnosis and do surgery to avoid progressive damage to liver. If there is progressive damage to liver early referral to liver transplant centre is advised which is not possible in developing countries like Bangladesh, Bhutan and Nepal. So surgical corrective procedure such as Kasai procedure remains the first line of treatment for most of the patient with Biliary Arteria (HA shah, 1994)

Even with clinically available methods the differentiation of Biliary Arteria from neonatal hepatitis or other causes of infantile cholestasis remain challenging. First, there is always the diagnostic delimita, second is the referral system. Third all the necessary investigations are not available at one centre. So there is delay for therapeutic intervention. In our study also most of the patient presented more than 60 days. There is well known fact the outcome is not favorable after 60 days. The abdominal wall of children is thin, ultrasonic inspection is repeatable, convenient and non-invasive. Due to these advantages and improvement in ultrasonic enhancement, USG is more eminent than other diagnostic methods (Carroll, 1982 & Lin WY, 1997). In 2003, Hee Jung et al and Tan et al claim that triangular cord sign and measuring the gall bladder length together are non-invasive, in-expensive and very useful marker for BA. Authors during their long clinical practice could hardly find any ultrasonologic findings as triangular cord in Bangladesh. In our study all the patient were evaluated by USG of whole abdomen after clinical and laboratory assessment suggestive of Biliary Arteria. The sonographic exam was performed by C1-D probe, 2-5 MHZ and 11L-D probe 4-10 MHZ. Infants were not feed for 4 hours before their examination. None of the patients were sedated. Extra hepatic bile ducts which have become scarred cords of tissue were observed in 19 patients where we called periportal fibrosis. In 1997 Park et al gave an opinion that using ultrasonography is a new and non invasive diagnostic tool for every year and definite diagnosis of BA.

In seventeen patient gall bladder was present which appeared to be irregularly contracted. The length was less than 1.5 cm long and lumen was seen. In 4 patients saccular well defined gall bladder was present and. In four patients gall bladder was absent (Ikeda, 1998 & Lenton, 1992).

Contraction of gall bladder has been reported in patient BA. M Nemati et al showed HIDA scan was completely sensitive in diagnosis of EHBA. Among 20 patients with HIDA scan and percutaneous liver biopsy, 18 patients revealed features of Biliary Arteria.

With all modalities mentioned above we diagnosed 18 subjects as Biliary Arteria and undergone Kasai Procedure. All patients were done under general anesthesia with endotracheal intubation with muscle relaxant with average duration of 3 hours. Sixteen patients revealed absence of biliary tract and contracted gall bladder. The two patients had common bile duct and normal looking gall bladder. However the content of gall bladder was white bile. The tissue from the extrabiliary tract was sent for histopathology. All of

them revealed periportal fibrosis and chronic inflammatory cells.

In extra-hepatic Biliary Arteria surgical corrective procedure like Kasai hepatic portoenterostomy remain the first choice for Paediatric surgeon (Shah et al and Choi et , 1996) However various treatment have been tried and could not have good results like Kasai procedure. The primary aim of the surgery is to resect the fibrous bile duct remnant followed by Roux-en-Y anastomosis of jejunum to porta hepatis (Zukotysnki, <http://medicine.medscape.com>).

#### CONCLUSION;

We propose that periportal fibrosis and contracted gall bladder less 15 mm and doesn't change at feeding and fasting state is highly suggestive of Biliary Arteria. This is non invasive, rapid, simple and reliable diagnostic means for evaluation of infants with persistent conjugated hyperbilirubinemia.

This study shows that simple ultrasonography findings help in diagnosis of Biliary Arteria avoiding liver biopsy and expensive investigation. This is even more helpful in Indian subcontinent where people cannot afford all the investigations. Further there is delay in making surgical intervention because all the investigations are done in different departments in different institutions. There is delay when the patient approaches for surgery.

**Limitations;** i) Level of awareness and education level of people regarding BA.

ii) Investigations like MRCP and intraoperative cholangiogram are not done because patient cannot afford them

iii) All Ultrasonography examinations were performed by single operator. Operator experience puts a great value in the detection and interpretation of US finding.

#### Recommendations:

i) Mothers of babies should be alert of persistent hyperbilirubinemia and seek medical help without delay.

ii) Biliary Arteria should be ruled out in all neonates with persistent jaundice through screening with abdominal scan.

#### REFERENCES

1. AK Magd k Ahmed, FS Maha, M.E Nehal, M.E Hana, KA Mohammed AAhmed, EE Mohammad Manoochehr et al ,2001, Evaluation of Triangular Cord sign in diagnosis of Biliary Arteria in Paediatric, 108(2), 416-420. Available at [www.ncbi.nlm.nih.gov/pubmed/11483808](http://www.ncbi.nlm.nih.gov/pubmed/11483808)
2. Carroll BA ,Oppenheimer DA, Muller H.H ,1982, High frequency real time ultrasound of neonatal Biliary system Radiology ,145;437-440
3. HA Shah W.Spivak, 1994, Neonatal Cholestasis, New approach to diagnostic evaluation and therapy Pediatric Clin North Am, 41(5) 943-966.
4. Hee Jung Lee, sung Moon lee, Woo-Hyun park, Soon-ok choi, 2003, Objective criteria Of Triangular Cord sign in Biliary Arteria On Us scan, radiology 229,395-400, doi 10.1148/radio292020472
5. Ikeda S.Sere Yoshiro H, Uchinos, Akizuki M, Kondo Y, 1998, Gall Bladder contraction in Biliary Arteria, a pitfall of ultrasound Diagnosis, Pediatric Radiology, 451-453.
6. Kimio kanegawa, Yoshinobu, Akasaha, Er Kitamura ,Syoji Nishiyama, Toshihiro Muraji, Eiji Nishijima, Shikisaton and Chikara Tsugawa, 2003 Sonographic diagnosis of Biliary Arteria in Arteria in Pediatric patients using Triangular cord sign versus gall bladder length and contraction, 181(5)D, American Journal of Roentgenology, <http://www.ajronline.org/doi/full/10.2214/ajr.181.5.1811387>
7. K Zukotysnki, E Clin Biliary Arteria, Medscape reference

- retrieved from <http://emedicine.medscape.com/article-406335-overview>
8. Lentonen L, Svedstrom E, Korvenranta H, 1992, the size and contractility of gall bladder infants, *pediatric radiology* 22:515-518
  9. Lin WY, Lin CC, Chanylai SP, Shen Y, Wung SJ, 1997, Comparison technetium of TCC-9mm disofenin cholescintigraphy with ultrasonography in differentiation of biliary atresia from other forms of neonatal jaundice *paed surgery int*, 12;30-33
  10. Mittal V, Saxena AK, Sodhik Thapa BR, Rao KI, Das A et al, 2011, Role Of abdominal sonography in the preoperative diagnosis of extra hepatic Biliary Atresia in infants Younger than 90 days. *AJR AM J Roentgen*, 196 W438-W445, Available at [www.ncbi.nlm.nih.gov](http://www.ncbi.nlm.nih.gov)
  11. M. Nemati, M. Rafecy and AB Shaker, 2009, Ultrasound findings in Biliary, The Role Of Triangular Cord sign, *Pakistan Journal Of biological Sciences* 12;95-97, doi 10.3923/pjbs.2009.95.97, <http://scialert.net>, Accessed on 5/17/2016
  12. Ohl R. Biliary Atresia, Balistreri WF, Ohl R. *Todoni Tuscida Y*, 1997, Hepatobiliary pancreatic and splenic disease in Children. *Isted. Amsterdam Elsevier*; 231-260.
  13. Shi-Xing La, Yao Zhang, Mei Sun Bo, Shi Zhong-Y XU, Ying Huang and Zhi Qn Mao, 2008, Ultrasonic diagnosis of biliary Atresia a retrospective analysis of 20 patients, *World J Gastroenterol* 14(22), 3579-3588, doi 10.3748/wjg.14.3579. Accessed on 5/21/2016
  14. So. Choi, WH park, HJ Lee, SK WOO, 1996, triangular Cord, a sonographic findings, applicable in the diagnosis of biliary atresia, *journal paediatric Surgery* 31(3), 363-366
  15. Tan Kendrick Ap, Phua KB, Ooi BC, Subramaniam R, Tan CE, Goh AS, 2000, making diagnosis of biliary Atresia using triangular Cord sign and gall bladder length. *Pedia Radio* 30(2); 69-73 Available on <http://www.ncbi.nlm.nih.gov/pubmed/10663514>, Access on 5/23/2016
  16. Y. weera Kkody and G singh et al Biliary Atresia, retrieved from [Radiopedia.org \(Http:// radiopedia.org/articles/biliary atresia\)](http://radiopedia.org/articles/biliary-atresia).
  17. WH park So Chi HJ lee, SPkim, SK Zeon, SJ Lee, 1997, A new diagnostic approach to biliary Atresia who emphasis on the ultrasonographic triangular cord sign comparison of ultrasonography hepato biliary scintigraphy and liver needle biopsy in the evaluation of infantile cholestasis, *paedi surgery* 32(11), 1555-1559.