



RETINAL AND CHOROIDAL THICKNESS MEASUREMENTS BY CIRRUS, DRI, AND ANGIOVUE OPTICAL COHERENCE TOMOGRAPHY DEVICES IN HIGH MYOPIA EYES

Nigar Alimova Department of Ophthalmology University of Medical Sciences Ankara, Turkey

Zeliha Yazar Department of Ophthalmology University of Medical Sciences Ankara, Turkey

ABSTRACT

Purpose: This study aimed to examine the central fovea and subfoveal choroidal thickness with the uses of three different brands of Optical Coherence Tomography (OCT); compare their effectiveness and reliability.

Methods: 146 patients (with 252 eyes) were purposefully selected diagnosed with visual disorders such as high myopia (N=58, study group 1), degenerative myopia (N=48, study group 2) and emmetropia (N=122, control group). Paired t-test and the Intraclass Correlation Coefficients (ICCs) were applied to obtain any correlation among groups and the devices.

Results: Findings showed that no significant differences exist among the subjects for the CFT. Intra-class correlations were calculated as 0.674, 0.713 and 0.786 for the devices. Similar results were obtained in degenerative myopia and different scores between emmetropia and high myopia ($p < 0.05$).

Conclusion: Statistically significant differences among patients' initial measurements of central foveal and subfoveal choroidal thicknesses and high correlations were measured among the devices.

KEYWORD

Axial length, central foveal thickness, subfoveal choroidal thickness, optical coherence tomography, OCT devices.

ARTICLE HISTORY

Submitted: 06-02-2019

Accepted: 30-03-2019

Published: 10-05-2019

*Corresponding Author Nigar Alimova

Department of Ophthalmology University of Medical Sciences Ankara, Turkey, nigulya-t@mail.ru

INTRODUCTION

Pathological myopia, apart from high myopia, is commonly accepted as one of the most important eye diseases in the ophthalmology throughout the world. It differs from high myopia as present in any eyeball greater than 26.5 mm or refractive value greater than -6 diopter (D).¹ As generally referred to as a malignant and degenerative myopia, it may cause permanent damage to the eye as a result of degenerative disorders caused by myopia, sclera, choroid, and retinal pigment epithelium. Such disorders contain vitreous liquefaction, posterior vitreous detachments, crescent formation leading to peripapillary atrophy, chorioretinal atrophy, posterior staphyloma, Fuchs spots, the lacquer cracks, and optic disc deformities.²

A group of patients with such disorders mostly develop an abnormally thinner retinal and central choroidal thickness as well as noticeable complications such as foveoschisis, degenerative macular holes or choroidal neovascular membrane.³ In order to discover such complications on time, retinal and choroids should be periodically examined. Several devices are currently used in the ophthalmology market for this purpose. Especially, optical coherence tomography (OCT) devices and fundus cameras have gained popularity, since especially OCT devices operate in different wavelength and resolution, providing different retinal and choroidal measurements.⁴ Therefore, such results may reveal distinctive diagnostics and are the emphasis in follow-up and treatment processes.

OCT was initially developed by Huang and his colleagues at Massachusetts Institute of Technology in 1991.^{3,5,6} OCT has been as a useful noninvasive cross-sectional imaging technique in biological systems for the last two decades in the area of ophthalmology.⁷ Specifically, its usage involving enhanced depth imaging OCT, image averaging, and swept-

source OCT have been a great tool to investigate the choroidal anatomy with its visualization property.⁴

Recent studies examined OCT devices on various eye defects such as glaucoma, macular and nerve fiber layer thickness, central corneal thickness, macular thickness, and choroidal thickness.^{8,9-11} For example, Leite et al.⁸ compared the diagnostic abilities of Spectralis, Cirrus, and RTVue devices. 233 eyes of 149 participants were selected as one control and one treatment group. Of them, 107 were healthy and 126 were diagnosed with glaucomatous. The findings showed that RNFL thickness parameter with the largest area under receiver operating characteristics (AUC) was higher for Spectralis (0.88) and global RNFL thickness for Cirrus (0.88) and RTVue (0.87). The measurements of the devices exhibited no significant difference in terms of the pairwise comparison among the ROC curves for all parameters except for the nasal quadrant. In conclusion, they reached the conclusion that even though all three OCT instruments measure different levels of resolution and acquisition, their ability to identify glaucoma was alike.

In a different study, Kiernan, Mieler, and Hariprasad studied the spectral-domain (SD) optical coherence tomography (OCT) and their resolution retinal imaging systems.¹² They concluded that nine distinctive SD-OCT devices would soon be commercially available based on their premises in a nonproprietary mathematical formula of Fourier transformation. Furthermore, SD-OCT instruments were found to derive increased retinal thickness and decreased nerve fiber layer thickness measurements. They strongly believed that the devices will continue to provide new understandings about ocular structure and diseases through improving technology.

Sung and his colleagues conducted another study to compare

thicknesses of the retinal nerve fiber layer (RNFL) measured by Cirrus HD and Stratus OCT instruments.¹⁰ They used a cross-sectional study with 6 healthy, 48 glaucoma subjects, and 55 subjects with glaucoma. The participants were measured by a single trainer operator by using the devices. RNFL thickness as determined by two OCT devices showed a correlation with $r = 0.94$ and $P < 0.001$, but significantly distinct measurements were found. Also, there existed some significant differences in RNFL thickness and normative classification despite a high degree of correlation on the RNFL thickness. Largely, Cirrus OCT showed more sensitive and higher specificity.

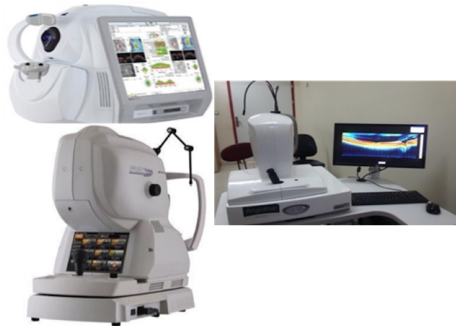

Fig. 1. OCT devices examined in the study (Cirrus HD-OCT, AngioVue HD-OCT, DRI HD-OCT Angio Triton SS)

As illustrated in figure 1, Cirrus HD-OCT Model 500, a type of Fourier-domain spectral SD-OCT, was used in the clinics in 2007 and examined for the study. It has advantages of the ability providing high resolution of the images, regression analysis, and fast screening (200 and above). The second device had a similar type of OCT technology, AngioVue HD-OCT Angio. It was initially developed by an American company. The last device was DRI HD-OCT Angio Triton SS, a type of swept source OCT, developed by a Japanese company in 2010. It utilizes a single and adjustable laser light that scans a wide wavelength spectrum at the center. It is an easy to use device and provides a high penetration on choroidal evaluations with its resolution (2 microns).¹³⁻¹⁹

METHODS

We studied the retinal and choroidal thickness measurements of pathologic myopia patients by 3 different OCT devices at our clinic. Specifically, measurements of pathologic myopia and the control group emmetropic patients were compared. 58 eyes of 36 patients with high myopia (-6D and over or eye axial length of 26 mm) and 72 eyes of 48 patients (above -6D or eye axial length of over 26.5 mm) were labeled as two study groups. In addition, 122 eyes of 62 emmetropic patients (control group) were evaluated retrospectively. Data collection process took place at a Training and Research Hospital in Ankara, Turkey. All of the subjects were purposefully selected. Our selection followed the below criteria:

- 6D and above or 26 mm axial length, mild degenerative signs (high myopia group),
- 6D and above or 26.5 mm axial length, prominent degenerative signs (degenerative myopia group),
- No refractive, glaucoma and vitreoretinal surgery history (excluded from the study). The participants are shown in Table 1.

Table 1. The subjects and the groups involved in the study

Groups	Number of Patients	Number of Eyes	Average Age (18-75)
Degenerative Myopia (Study G. 1)	48	72	47.16
High Myopia (Study G. 2)	36	58	40.77
Emmetropia (Control G.)	62	122	41.06
Total	146	252	43*

*No significant differences of ages among the groups ($p=0,061$)

The participants with the Emmetropic were required to have full vision without correction, not to have any history of previous intraocular surgical history and be an absence of ocular pathologies such as cataract, glaucoma, diabetic retinopathy and retinal detachment. All participants had a complete ophthalmologic examination, containing systemic and ocular disease inquiry, manifest refraction and axial length of the eye measurement, biomicroscopic examination, central foveal and subfoveal choroidal thicknesses by three different devices.

Data were analyzed with SPSS v.11.5 package program. In statistical analysis, one-way ANOVA and Bonferroni test was utilized for comparison of the variables with normal distribution among the three groups. Paired t-test was used for intra-group comparison. The compatibility of the devices with each other was examined by the Interclass Correlation Analysis (ICC). The relationships were evaluated by Spearman Rank correlation analysis. A patient consent form from each participant was collected and ethical forms were approved by the ethical committee at the University of Health Science Hospital.

RESULTS

The main purpose of this study was to compare the effectiveness of three different OCT devices on myopia patients. Of the participants, 48 (29%) were degenerative myopia (experimental group I), 36 (23%) were high myopia (experimental group II), and 62 (48%) were the control group. The ages ranged between 18 and 75 with an average of 43. Each group had the same number of male/female ratios ($p = 0.726$) (Table 2).

Table 2. Demographics of the Participated Subjects

		Degenerative Myopia (%)	High Myopia (%)	Control Group (%)	P-value
Gender	Male	18 (76)	10(56)	22 (72)	0.73
	Female	30 (124)	26 (144)	40 (128)	
	Total	48	36	62	
	Ave. ±SD	47.16 ± 10.62	40.77 ± 11.01	41.06 ± 9.69	0.06
	Min-Max	25-64	18-60	18-62	

The participants diagnosed with the systematic disease were equivalent among all three groups ($p = 0.777$) and the ones without it were also the same ($p = 0.778$).

Central Fovea Thickness (CFT)

Central fovea thicknesses of the subjects were measured by the devices and the findings were illustrated in table 3.

Table 3. Comparison of Central Fovea Thickness of the subjects by the OCT devices

	Degenerative Group	High myopia Group	Control Group	P-value
Cirrus HD-OCT 500 (µm)	246.8 ± 23.30	247.31 ± 30.11	240.83 ± 23.30	0.272
AngioVue HD-OCT (µm)	240.97 ± 28.35	240.79 ± 26.70	252.39 ± 19.05	0.028*
DRI HD-OCT Angio Triton SS (µm)	243.30 ± 29.85	244.06 ± 22.59	237.72 ± 24.41	0.433
Mean (µm)	243.69 ± 21.17	244.9 ± 26.46	243.64 ± 66.76	0.296

As specified above, no significant difference was found between the measurements of central fovea thickness obtained by Cirrus and AngioVue, except the control group. Measurements in AngioVue were found with a difference of

20.15 μm ($p = 0.023$). Furthermore, a moderate positive correlation existed between Cirrus and AngioVue ($r = 0.51$), low positive correlation between Cirrus and DRI ($r = 0.36$), and moderate correlation between AngioVue and DRI ($r = 0.50$).

A positive high correlation ($\text{ICC} = 0.71$) appeared among the groups. Specifically, three devices showed similar results in the degenerative group. Cirrus and AngioVue machines' measurements showed a high positive correlation ($r = 0.66$) and a low positive correlation among others in the high myopia group. A high intra-class coefficient was calculated ($r = 0.79$). In the control group, Cirrus and AngioVue showed a high correlation ($r = 0.73$). There was a moderate correlation between Cirrus/DRI and AngioVue/DRI and ICC between them was calculated 0.68. The devices showed compatibility based on the measurements.

There existed a significant difference between Cirrus/AngioVue and DRI/AngioVue in the control group ($p=0,00*$). While Cirrus and DRI were showing similar measurements, AngioVue was measuring about 20.15 μm higher.

Subfoveal Choroidal Thickness (SFCT)

Subfoveal choroidal thickness measurements by the devices showed a significant difference among the groups ($p=0,000*$). The highest mean of SFCT (291,12 μm) was calculated in the control group and the lowest mean (123,97 μm) was calculated in the degenerative myopia group (Table 4). Mean SFCT in the degenerative myopia group was found to be 100 mm and 157 mm thinner than myopia and the emmetropia groups, respectively.

Table 4. Comparison of Subfoveal Choroidal Thickness of the subjects by the OCT devices

	Degenerative Group	High myopia Group	Control Group	P-value
Cirrus HD-OKT 500 (μm)	125.66 \pm 59.45	226.68 \pm 43.58	285.83 \pm 50.87	0.000*
AngioVue HD-OKT (μm)	121.50 \pm 63.54	227.62 \pm 60.34	265.85 \pm 56.56	0.000*
DRI HD-OKT	121.63 \pm 56.82	197.72 \pm 63.78	291.12 \pm 52.05	0.000*
Angio Triton SS (μm)	56.82	63.78	52.05	
Average (μm)	123.97 \pm 59.26	227.34 \pm 55.91	291.12 \pm 52.05	0.000*

In the degenerative myopia group, there was a high positive correlation between Cirrus and AngioVue ($r = 0.88$), between Cirrus and DRI ($r = 0.62$), and between AngioVue and DRI ($r = 0.64$) based on the subfoveal choroidal thickness measurements. The intra-class coefficient was calculated as high as 0.89 among the groups. There existed a high positive correlation between Cirrus and AngioVue ($p = 0.65$), a moderate relationship between Cirrus and DRI ($p = 0.52$), and between AngioVue and DRI ($p = 0.52$) in the high myopia group. The ICC was found 0.84 between them.

In the control group, a weak positive correlation was identified between Cirrus and AngioVue ($p = 0.39$), as well as Cirrus and DRI ($p = 0.39$). However, there was a moderate correlation between AngioVue and DRI ($p = 0.58$). Overall, the ICC was calculated to be high among them ($\text{ICCs} = 0.70$).

As for the difference, there was a significant difference between Cirrus and AngioVue, AngioVue and DRI in the high myopia group and all three of them among the control group. In conclusion, the AngioVue machine measured higher values.

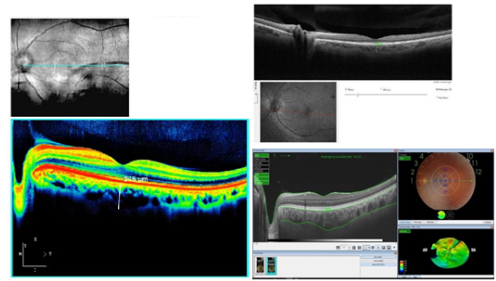


Fig. 2. Manually measured subfoveal choroidal thickness of emmetropic person in Cirrus, AngioVue, and DRI devices

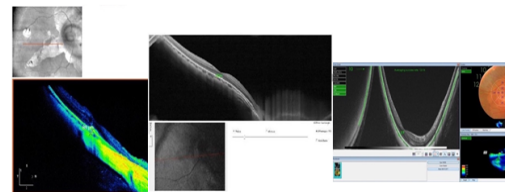


Fig. 3. Automatic and manual subfoveal choroidal thickness measurement with Cirrus, AngioVue and HDI devices in a degenerative eye

DISCUSSION

Macular thickness was measured differently in the high refractive defects among various races, genders and age groups in many different geographical regions.²⁰ Mean foveal thickness was reported as 197.1 in a group of healthy emmetropic eyes by Straus.²¹ They also stated that no significant difference existed in the macular segment thickness (high myopia, low-moderate myopia, and non-myopic eyes) in a study.²² In addition, other researchers indicated that as severity levels of the myopia increases, macula thickness and volume decrease, but central fovea thickness increases.²²⁻²⁵

In our study, we found that central foveal thickness did not change with increasing axial length, aligned with the previous research findings.²²⁻²⁵ Also, it revealed that CFTs of high myopia groups had an average of 2-5 m thicker than degenerative myopia group and 5-6.5 m thicker than the emmetropia group. However, such differences were not statistically significant. In addition, Cirrus and AngioVue devices specifically exhibited similar measurements in terms of CFT.

When swept source OCT devices were launched in 2015, automatic measurement of the subfoveal choroidal thickness was made possible.²⁶ The SFCT of myopia person is usually thinner than others.²⁷ According to our findings, the highest choroidal thickness was found in the emmetropic group and the lowest values in the degenerative group. They showed statistically significant results ($p = 0.000$). Patients with and without posterior staphyloma in the degenerative group reported similar types of visions. Staphyloma did not significantly affect the visual acuity.

No significant difference was found in the degenerative myopia group in the case of SFCT among the devices. However, a significant difference was observed in the emmetropic and high myopia groups. Although Cirrus and DRI measured similar values, AngioVue showed higher measurements. This result might be due to the characteristics of the choroid boundaries for different groups, wavelengths and measurement protocols of the devices. Additionally, human measurement error or manual detection could be other issues for these unexpected results.

The choroid thickness was measured extremely thinner for

the degenerative myopia group and the presence of posterior staphyloma existed for most of the patients. We obtained similar results in this group regardless of the resolutions of the devices. Since only DRI device can perform an automatic segmentation to display chroido-scleral junction with Bruch membrane, a significant difference was found among the groups in the submeters of the SFCT. Further studies are needed to determine to what extent these differences depend on the features of the groups and how much they are based on the properties of the devices.

In conclusion, we compared the diagnostic usages of three independent OCT devices on the measurements of the central foveal and subfoveal choroidal thicknesses. Although they did not differ in patients' follow-ups, there existed statistically significant differences among the initial measurements of the central foveal and subfoveal choroidal thicknesses. Also, high correlations were found among the instruments. No significant difference was found in the degenerative myopia group.

Nevertheless, Cirrus and DRI devices in emmetropic and high myopia groups provided similar results, higher than AngioVue. For that reason, it is recommended that one should use the same devices for such measurements on follow up sessions. More comprehensive and rich results could be obtained for the choroidal thickness measurements especially in patients with different refractive errors with the addition of database by the OCT devices, that would provide automatic segmentation and numerical values. Therefore, we should keep in mind that the subfoveal choroidal thickness could yield distinctive results by various devices, which should not be ignored in the follow-ups. Also, further studies are needed with diverse patient groups.

REFERENCES

1. 2018-2019 Basic and Clinical Science Course Complete Test. Chicago: American Academy of Ophthalmology; 2019.
2. Curtin BS. The myopia: Basic science and clinical management. Philadelphia: Harper Row; 1985.
3. Huang D, Swanson EA, Lin CP, Schuman JS, Stinson WG, Chang W et al. Optical Coherence Tomography. *Science*. 1991;254 (5035):1178-1181.
4. Mrejen S, Spaide RF. Optical coherence tomography: imaging of the choroid and beyond. *Survey of Ophthalmology*. 2013;58 (5):387-429.
5. Vitale S, Sperduto RD, Ferris FL. Increased prevalence of myopia in the United States between 1971-1972 and 199-2004. *Arch Ophthalmology*. 2009;127 (12):1632-9.
6. Curtin BJ, Karlin DB. Axial length measurements and fundus changes of the myopic eye. *Am J Ophthalmology*. 1971;71 (1):42-53.
7. Leite MT, Rao HL, Zangwill LM, Weinreb RN, Medeiros FA. Comparison of the diagnostic accuracies of the Spectralis, Cirrus, and RTVue optical coherence tomography devices in glaucoma. *Ophthalmology*. 2011;118 (7):1334-9.
8. Jaffe GJ, & Caprioli J. Optical coherence tomography to detect and manage retinal disease and glaucoma. *American Journal of Ophthalmology*. 2004; 137(1): 156-169.
9. Guedes V, Schuman JS, Hertzmark E, Wollstein G, Correnti A, Mancini R et al. Optical coherence tomography measurement of macular and nerve fiber layer thickness in normal and glaucomatous human eyes. *Ophthalmology*. 2003;110 (1): 177-89.
10. Sung KR, Kim DY, Park SB, Kook MS. Comparison of retinal nerve fiber layer thickness measured by Cirrus HD and Stratus optical coherence tomography. *Ophthalmology*. 2009;116 (7):1264-70.
11. Bechmann M, Thiel MJ, Neubauer AS, Ullrich S, Ludwig K, Kenyon KR et al. Central corneal thickness measurement with a retinal optical coherence tomography device versus standard ultrasonic pachymetry. *Cornea*. 2001;20 (1):50-54.
12. Kiernan DF, Mieler WF, Hariprasad SM. Spectral-domain optical coherence tomography: a comparison of modern high-resolution retinal imaging systems. *American Journal of Ophthalmology*. 2010;149(1):18-31.
13. Ozcetin H, Sener B. Gozde kırılma kusurları ve uyum: miyopi ve tedavisi. Bursa: Nobel Medical Publishing; 2002.
14. Matsumara H. Prevalence of myopia and refractive changes in students from 3 to 7 years of age. *Surv. Ophthalmology*. 1998;44 (suppl.):109-115.
15. McCarty CA, Taylor HT. Myopia and vision. *American J of Ophthalmology*. 2000;129 (4):525-527.
16. Elcioglu M, Elcioglu T, Soylu T. Okul çocuklarında göz hastalıklarının taranması. 26. National Turkish Symposium. Bursa; 1992:76-79.
17. Otsuka J. Research on the etiology and treatment of myopia. *Acta Soc. Ophthalmology*. 1967;7:211-212.
18. Guler C, Gozun Refraktif Durumu, Muayene Yontemleri, Bolum 4, Temel Goz Hastalıkları, 1. Baskı, Aydın P, Akova YA eds. Ankara: Gunes Publishing; 2001.
19. Ting DS, Cheung GC, Lim LS, Yeo IY. Comparison of swept source optical coherence tomography and spectral domain optical coherence tomography in polypoidal choroidal vasculopathy. *Clin Exp Ophthalmology*. 2015; 43 (9):815-9.
20. Yilmaz I, Murat C, Satıcı T, Ozcelik F, Yazıcı AT, Demirok A. Sağlıklı gözlerde optik koherens Tomografi ile makuler kalınlık ölçümü: Yas ve cinsiyete bağlı değişimler. *Ege Medical Journal*. 2015;54 (1):15-18
21. Chan A, Duker JS, Ishikawa H, Ko TH, Schuman JS, Fujimoto JG. Quantification of photoreceptor layer thickness in normal eyes using optical coherence tomography. *Retina (Philadelphia, PA)*. 2006;26 (6):655-660.
22. Wu PC, Chen YJ, Chen CH, Chen YH, Shin SJ, Yang HJ et al. Assessment of macular retinal thickness and volume in normal eyes and highly myopic eyes with third-generation optical coherence tomography. *Eye (London)*. 2008;22 (4):551-5.
23. Lam DS, Leung KS, Mohamed S, Chan W, Palanivelu MS, Lui CC. Regional variations in the relationship between measurements in myopia. *Investigative Ophthalmology & Visual Science*. 2007;48:376-382.
24. Luo HD, Gazzard G, Fong A, Aung T, Hoh ST, Loon SC et al. Myopia, axial length, and OCT characteristics of the macular thickness in Singaporean children. *Investigative Ophthalmology & Visual Science*. 2006;47 (7):2773-81.
25. Zhang Z, He X, Zhu J, Jiang K, Zheng W, Ke B. Macular measurements using optical coherence tomography in healthy Chinese school-age children. *Investigative Ophthalmology & Visual Science*. 2011;52:6377-83.
26. Ruiz-Medrano J, Flores-Moreno I, Pena-Garcia P, Montero JA, Duker JS, Ruiz-Moreno JM. Macular choroidal thickness profile in a healthy population measured by swept source optical coherence tomography. *Investigative Ophthalmology & Visual Science*. 2014; 55 (6):3532-42.
27. Fujiwara T, Imamura Y, Margolis R, Slakter JS, Spaide RF. Enhanced depth imaging optical coherence tomography of the choroid in highly myopic eyes. *American J of Ophthalmology*. 2009;148 (3):445-50.