



FIBROADENOMA REGRESSION IN RESPONSE TO CENTCHROMAN

General Surgery

Dr. Taralkumar Chaudhari

Senior Resident, Department of General Surgery, SMIMER, Surat

Dr. Archana Nema*

Additional Professor, Department of General Surgery, SMIMER, Surat*Corresponding Author

ABSTRACT

Benign breast diseases account for majority of breast pathology in young women. Fibroadenoma is a common cause of discrete, firm and mobile lump in the breast in young girls between ages 15 to 25 years. It is considered an "aberration in development and involution" of ductolobular tissue in the breast and not a true neoplasm.[1] Fibroadenoma begins as hyperplasia of the lobules from "terminal ductal lobular units". Most of them remain static, but some increase in size to more than 5 cm when they are termed as "Giant Fibroadenoma". Nearly 10-15% of lesion regress spontaneously over the period of 6 to 60 months.[2] This study aims to investigate the role of Centchroman in regression of fibroadenoma and to study the association of hormonal receptors with degree of regression. The study was carried out at the outpatient clinic of Department of Surgery, Surat Municipal Institute of Medical Education and research, Surat, Gujarat from November 2016 to November 2017. Patients aged more than 17 years up to 30 years with fibroadenoma were included. Patients with fibroadenoma of size up to 5 cm without polycystic ovarian disease were included in the study. All the patients were prescribed centchroman 30 mg on alternate day for a period of 3 months and were followed up for 6 months. Patients were followed at 1,2,4,8,12 and 24 weeks to assess response to centchroman.

KEYWORDS

Fibroadenoma, Benign breast disease, Centchroman, Ormeloxifene, SERMs,

Introduction:

Fibroadenomas are the most common benign breast masses in younger women aged less than 30 years. It is considered an "aberration in development and involution" of ductolobular tissue in the breast and not a true neoplasm.[1] Fibroadenoma begins as hyperplasia of the lobules from "terminal ductal lobular units" which progressively increases in size. Few lesions regress spontaneously over the period 5 years.[2] Simple fibroadenoma is usually managed by natural observation, as they are benign and asymptomatic without any risk of future cancer.[3] Complex fibroadenoma is associated with moderate risk of cancer 3.1 times and those associated with atypia (relative risk of >2) or family history of breast cancer should be excised.[1,3,4] Some patients prefer to have the lump excised because of pain, discomfort, psychological reason, or fear of cancer.

Hormonal manipulation has been attempted to suppress the growth of fibroadenoma with antiestrogenic drug tamoxifene as fibroadenoma is considered to arise from hyper-responsiveness of lobular tissue to estrogen.[5,6,7] Centchroman had been prescribed to suppress the proliferation of ductolobular tissue of fibroadenoma. Centchroman is a nonsteroidal antiestrogen drug developed by the Central Drug Research Institute, Lucknow, India. It is a selective estrogen receptor modulator with weak agonist on endometrium and strong antagonist on breast ductolobular epithelium action.[8] It is free from side effects commonly associated with steroidal oral contraceptives like nausea, vomiting, weight gain and dizziness. It does not delay in return of fertility. It maintains normal ovulatory cycles because the low dose minimizes any effect on the hypothalamic-pituitary-ovarian axis. It has no side effects except that it prolongs the menstrual period duration in about 10% of cases. Because of the advantages of this drug as a nonsteroidal antiestrogen with almost no side effects, it was used in the treatment of the benign breast diseases.

Materials and Methods: This study was conducted between November 2016 to November 2017 in the surgery outpatient department at Surat Municipal Institute of Medical Education and Research, Surat, Gujarat. All patient up to age 30 years presenting with benign breast diseases were evaluated for this study. All the patients with fibroadenomas of size less than 5 cm, after triple assessment (clinical examination, Ultrasonography of breast and FNAC/Ture-cut biopsy) were included in the study. Patients having polycystic ovarian disease, cervical hyperplasia, past history or family history of breast cancer, complex fibroadenoma those associated with atypia, lactation period of first 6 months and pregnancy and those wishing to conceive in the near future were not included in the study.

All the patients with fibroadenoma were followed up at 1,2,4,8,12 and

24 weeks. The response of fibroadenoma to centchroman was decrease in size of lump measured clinically and with help of ultrasound at the beginning, at the end of 4 weeks, 8 weeks, 12 weeks and 24 weeks.

Results: This study was conducted on a total of 37 patients whose age ranged from 17 to 35 years. Most common age group was 17 to 23 years with mean age of presentation was 24.81 ± 5.89 years. Out of total 37 patients of fibroadenoma presented with complain of breast lump, 5 patients (13%) had complain of pain, tenderness was present in 5 patients (21%). Out of 37 patients, 14 patients (38%) had fibroadenoma on right side and 18 patients (49%) had fibroadenoma on left side. Total cases of Unilateral fibroadenoma were 32 patients (87%). Patients with bilateral fibroadenoma were 5 (13%). Fibroadenoma was located in lower outer quadrant in 13 patients (35%), upper outer quadrant in 11 patients (30%), upper inner quadrant in 5 patients (14%) and lower inner quadrant in 2 patients (5%). Fibroadenoma was multiple in 6 patients (16%).

At the end of 2 weeks, fibroadenoma was reduced in 03 patients (8%), and showed no changes in 34 patients (92%). At the end of 4 weeks, fibroadenoma completely disappeared in 2 patients (6%), was reduced in 6 patients (16%), and showed no changes in 29 patients (78%). At the end of 8 weeks, fibroadenoma completely disappeared in 6 patients (16%), was reduced in 10 patients (27%), and showed no changes in 21 patients (57%).

At the end of 12 weeks, fibroadenomas had completely disappeared in 13 patients (35%) and were reduced in 11 patients (30%). 3 patients in whom fibroadenoma completely disappeared on clinical examination were detected to had sub centimeter size fibroadenoma on ultrasound examination. There was no change in the size of fibroadenoma in 11 patients (30%).

At the end of end of 24 weeks, fibroadenoma completely disappeared in 12 patients (35%), were reduced in size in 12 patients (35%) and no change in the size of lump in 11 patients (30%). During follow-up of 6 months none of the fibroadenomas that disappeared recurred.

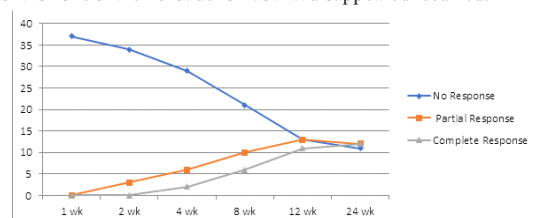


Fig:1 Effect of centchroman on fibroadenomas

Amenorrhoea was observed in three patients during the treatment period. They returned to normal cycle at 6 months follow up.

Discussion: Fibroadenomas are commonly seen in young female in surgical outpatient department. Breast lump being the most common presentation with peak incidence at around 20 years of age.[1] Many young women come with complain of breast lump and fear of having cancer. It is emotionally disturbing for young women. Even after proper counseling regarding the condition, many young women prefer to get it excised. Fibroadenoma excision leaves the scar on the breast and may damage the mammary duct if present near the nipple areola complex. There is a wide discrepancy in the natural history of fibroadenoma regarding the change in size over time. Many fibroadenoma, if left alone, will remain static or gradually increase in size until 1–3 cm in diameter in 1–5 years. Thereafter, it is likely to remain static for the rest of patient's life or gradually decrease in size. Fibroadenoma has chance of spontaneous natural regression of about 30% over a period of years. Khanna et al.[9] and Viviani et al.[6] described the drug therapy for fibroadenoma. Viviani et al. evaluated the effect of tamoxifene. Tamoxifene is an antiestrogenic drug shows regression of fibroadenoma size by about 20% in the treatment arm. Khanna et al. evaluated estrogen receptor positivity and effect of danazol on fibroadenoma. They found that 62% of fibroadenoma responded to danazol, and response to danazol was significantly greater in ER-positive fibroadenoma.

Centchroman (Ormeloxifene) is a nonsteroidal antiestrogen drug developed by the Central Drug Research Institute, Lucknow, India. It is a selective estrogen receptor modulator with weak agonist on endometrium and strong antagonist on breast ductolobular epithelium action. It is free from side effects commonly associated with steroidal oral contraceptives like nausea, vomiting, weight gain and dizziness. It does not delay in return of fertility. It maintains normal ovulatory cycles because the low dose minimizes any effect on the hypothalamic-pituitary-ovarian axis. It has no side effects except that it prolongs the menstrual period duration in about 10% of cases. Because of the advantages of this drug as a nonsteroidal antiestrogen with almost no side effects, it was used in the treatment of the benign breast diseases. There was a gradual decline in volume with Centchroman till the end of study. The serial volume measured by ultrasound during the study and at the end of treatment period also showed significant difference. At the end of study, fibroadenoma had completely disappeared in 14 patients (38%), were reduced in size in 12 patients (32%) and no change in size in 11 patients (30%). During follow-up of 6 months none of the fibroadenomas that disappeared recurred.

Conclusion: Centchroman with its antiestrogenic effect on breast found to be responsive in the treatment of fibroadenomas without any significant side effects. However, the long term results of centchroman on recurrence after treatment and long term side effects need to be studied on larger scale.

References:

1. Dupont WD, Pad FF, Hartmann WH et al (1993) Breast cancer risk associated with proliferative breast disease and atypical hyperplasia. *Cancer* 71:1258–65
2. Santen RJ, Mansel R (2005) Current concepts: benign breast disorders. *N Engl J Med* 353:275–85
3. Dupont WD, Page DL, Parl FF et al (1994) Long-term risk of breast cancer in women with fibroadenoma. *N Engl J Med* 331(1):10–5
4. Barton SA, Pathak DR, Black WC (1987) Prevalence of benign, atypical and malignant breast lesion in populations at different risk of breast cancer. *Cancer* 60:2751–60
5. Greenblatt RB, Dmowski WP, Mhesh VB et al (1971) Clinical studies with an antigonadotrophin-Danazol. *Fertil Steril* 22:102–112
6. Viviani RS, Gebrim LH, Baracat EC, De Lima GR (2002) Evaluation of the ultrasonographic volume of breast fibroadenomas in women treated with tamoxifen. *Minerva Gynecol* 54(6):531–5
7. Hughes LE (2000) Fibroadenoma and related tumours. In: Hughes LE, Mansel RE, Webster DJT (eds) *Benign disorders and diseases of the breast*, 2nd edn. Saunders, London, pp 73–94
8. Nityanand S, Chandrawati X, Singh L, Srivastava JS, Kamboj YR (1998) Clinical evaluation of Centchroman: a new oral contraceptive. In: Puri CP, Vanlook PF A (eds) *Hormone antagonists for fertility regulation*. Indian Soc Study Reprod Fert, India, Bombay, pp 223–30
9. Khanna AK, Tapodar JK, Khanna HD (2002) Behaviour of estrogen receptor, histological correlation and clinical outcome in patients with benign breast disorder. *Eur J Surg* 168:631