



A GROSS ANATOMICAL STUDY OF THE RELATION OF EXTERNAL BRANCH OF SUPERIOR LARYNGEAL NERVE TO SUPERIOR THYROID ARTERY

Anatomy

**Dr Namitha
Viswanath**

Associate Professor Department of Anatomy Government Medical College, Kozhikode Kerala

ABSTRACT

Relation of External branch of superior laryngeal nerve (EBSLN) to superior thyroid artery and upper pole of thyroid gland is a key point during thyroid surgery. This study emphasis on this relation thereby preventing injury to this nerve which may affect the phonation of the patient after thyroidectomy. **Materials and methods** A cadaveric study in Department of Anatomy, Government Medical College, Kozhikode where 50 thyroid glands (40 males and 10 females) were dissected carefully. Relation of EBSLN to superior thyroid artery was noted and this relation was categorized with Cernea's classification. **Results** a) In 53% of cases the nerve was crossing the artery less than 1 cm from the upper pole of thyroid gland (Type 2a of Cernea's classification) b) In 34% of cases the nerve was crossing the artery below the upper pole of thyroid gland (Type 2b of Cernea's classification) c) In 13% of cases the nerve was crossing the artery more than 1cm from the upper pole of thyroid gland (Type 1 of Cernea's classification) **Conclusions** This study highlights on Relation of EBSLN to superior thyroid artery which helps to reduce the complications during thyroidectomy

KEYWORDS

External branch of superior laryngeal nerve, Superior thyroid artery, Thyroidectomy

Relation of External branch of superior laryngeal nerve to superior thyroid artery and upper pole of thyroid gland is a key point during thyroid surgery.

Injury to External branch of superior laryngeal nerve resulting in paralysis of cricothyroid muscle was first described in 1906. injury to this nerve results in hoarseness and significant disability in phonation.

One of the earliest cases reported goes back to 1935, when the famous opera singer, Amelita Galli-curci, suffered injury to her External branch of superior laryngeal nerve after thyroid surgery.

Injury to External branch of superior laryngeal nerve was well documented by Drouilas et al 1976 and Friedman and Toriumi in 1986.

In 1987 Lennquist et al described the EBSLN as ".....the neglected nerve in thyroid surgery despite the fact that injury to this nerve can cause significant disability in phonation"

A detailed description of External branch of superior laryngeal nerve was given by Cernea et al in 1992. They put forward a classification which later was called Cernea's classification. They divided the nerve into three types, Type 1, Type 2a, Type 2b.

In Type 1, External branch of superior laryngeal nerve crosses the superior thyroid artery, 1 or more cm superior to the apex
In Type 2a External branch of superior laryngeal nerve crosses the superior thyroid artery, less than 1 cm from superior thyroid pole
In type 2b External branch of superior laryngeal nerve crosses inferior to the apex of superior thyroid artery

In their study type 1 was noted in 60% of the cases, type 2a in 17% of cases and type 2b in 20% of cases. They stated that type 2a and 2b are at increased risk during thyroid surgery. The nerve was not crossing the artery in 3% of cases (type ni)

Antonius Kierner et al in 1998 did a study to determine the course of External branch of superior laryngeal nerve and its relationship with superior thyroid artery. 31 cadavers of both sexes ranging from 50 to 94 years were included in this study. They categorised it into 4 types

In Type 1, External branch of superior laryngeal nerve crosses the superior thyroid artery, 1 or more cm above the upper pole of thyroid gland
In Type 11 -External branch of superior laryngeal nerve crosses the superior thyroid artery, less than 1 cm above the upper pole of thyroid gland
In type 111- External branch of superior laryngeal nerve crosses superior thyroid artery under the cover of upper pole of thyroid gland
Type 1V- -External branch of superior laryngeal nerve descends dorsal to superior thyroid artery and only crossed the branches of superior thyroid artery
His observations were Type 1-42%, Type 11-30%, Type 111- 14%, and Type 1V- 14% Aina and Hisham in 2001 did a study to analyse the frequency and types of External branch of

superior laryngeal nerve. They emphasized the presence of a potential avascular space termed as the "space of Reeve" between the upper pole of thyroid and cricothyroid muscle, where easy identification of the nerve is possible. They categorised the External branch of superior laryngeal nerve in accordance with cernea's classification Type 1-17.8%, Type 2a- 44.4%, type 2b-37.8%. They reported a greater distribution of type 2b in Indian ethnic group when compared to Malaya and Chinese ethnic groups.

In 2002, Younes et al did a dissection in the thyroid region of five cadavers. They described a "cricothyroid space" and commented it as an avascular space medial to thyroid lobe and is a good starting point for thyroidectomy that allows easy and safe exploration of the region.

Seven et al did a study on the topographical anatomy of External branch of superior laryngeal nerve and dissected the thyroid gland and of External branch of superior laryngeal nerve in thirty cadavers. They applied the classification proposed by Cernea et al. They found that the of External branch of superior laryngeal nerve was consistent with Type 1 in 51.8%, Type 2 in 48.2%, Type 2a in 37.1% type 2b in 11.1%. No significant relationship was found between the type of nerve, gender and age.

Samet et al in 2006 studied the relationship between the External branch of superior laryngeal nerve to the upper part of thyroid gland. Forty neck halves of twenty cadavers were dissected.

In 22.5% of cases the of External branch of superior laryngeal nerve crossed the superior thyroid artery more than 1cm above the upper pole of thyroid gland (type 1 of Cernea) In 60%, External branch of superior laryngeal nerve crossed the superior thyroid artery, less than 1cm above the upper pole of thyroid gland (Type 2a of Cernea) In 17.5%, External branch of superior laryngeal nerve crossed the superior thyroid artery under the upper pole of thyroid gland (Type 2b of Cernea)

Anand Kumar Mishra in 2007, carefully studied the of External branch of superior laryngeal nerve and stated that a combined technique of lateralization of superior thyroid pole along with careful dissection of avascular cricothyroid space, intraoperative nerve identification, capsular dissection, skeletonisation and individual ligation of superior pole vessels, increase the rate of nerve identification and decrease nerve injury even in the absence of sophisticated equipment's. Out of 78 superior poles dissected, nerve was identified in 72 (92.31%). Identified nerves were classified according to Cerneas classification

Type 1-28.2%
Type 2a-53.54%
Type 2b -10.25% of cases.

Naidoo in 2007 studied the relation of External branch of superior

laryngeal nerve to the superior pole of thyroid gland. This study aimed at determining the shortest distance from the most superior point of thyroid gland to External branch of superior laryngeal nerve. He noted a mean distance from External branch of superior laryngeal nerve to the superior pole of normal thyroid gland as 5.76mm on right and 6.17mm on left side.

Chung et al in 2009 did a study to determine the anatomic features of External branch of superior laryngeal nerve in Chinese adults. They analysed the anatomic distribution of 86 External branch of superior laryngeal nerve in 43 cadavers, obtained from National Defence Medical Centre, Taiwan. They classified the External branch of superior laryngeal nerve based on Cernea's classification. Their results were Type I in 16.2%, Type 11a 39.5%, Type 11b in 38.8% and in 6% of cases, nerve did not cross the superior thyroid artery (type ni)

Thejodhar in 2009 reported a case where External branch of superior laryngeal nerve has presented one medial and 3 lateral branches. Medial branch was running on the surface of inferior constrictor whereas 3 lateral branches were located lateral to superior thyroid artery. Of the 3 lateral branches the inner 2 lateral branches were piercing the substance of thyroid gland, whereas the lateral most one was communicating with the left sympathetic chain. He was able to observe a case of communication between the cervical sympathetic chain and External branch of superior laryngeal nerve. He stated that External branch of superior laryngeal nerve not only gives motor branches to cricothyroid muscle, but also branches to the thyroid gland.

Bohelto et al in 2009, elaborated the surgical protocol of the relation of External branch of superior laryngeal nerve to superior thyroid artery and put forward a newer classification.

Type I: Unidentified nerve

Type 11: External branch of superior laryngeal nerve crosses superior thyroid artery at a distance more than 1.5cm from the cranial border of thyroid gland

Type 111: External branch of superior laryngeal nerve crosses superior thyroid artery at a distance between 1 to 1.5cm from the cranial border of thyroid gland

Type 1V: External branch of superior laryngeal nerve crosses superior thyroid artery less than 1cm from the cranial border of thyroid gland

Type V: External branch of superior laryngeal nerve crosses below the cranial border of thyroid lobe
The results were as follows

Type 1-11.88%
Type 11- 13.86%
Type 111- 34.65%
Type 1V-38.61%
Type V- 1%

MATERIALS AND METHODS

This study on thyroid gland was undertaken in 50 cadavers (40 male and 10 female). 28 of them were adults and 22 fetuses. The study of the adult cadavers was undertaken in the specimens assigned for dissection of undergraduate students of Government Medical College, Kozhikode for a period of 2 years.

The fetuses for the study were obtained from Institute of Maternal and Child Health attached to Government Medical College, Kozhikode. Ethical committee approval was obtained. The fetuses were preserved in 37% commercial formalin by injecting the material into the anterior fontanelle (about 100cc), the right and left side of chest cavity (about 50cc) and peritoneal cavity (about 300cc). Multiple injections were also given into the extremities. The fetuses thus injected were kept immersed in large buckets containing formalin until they were taken out for dissection.

A midline incision, extending from symphysis menti to suprasternal notch and 2 lateral incisions extending from suprasternal notch laterally was made. Skin, platysma and investing layer of deep cervical fascia were turned laterally. For better view of thyroid gland, strap muscles were detached from the upper end and turned down. The gross anatomical features of thyroid gland were looked. Arterial supply of

thyroid gland was observed. Relation of External branch of superior laryngeal nerve to superior thyroid artery was noted. Crossing over of superior thyroid artery and External branch of superior laryngeal nerve was categorized with Cernea's classification.

BIostatistics

1. QUALITATIVE DATA

The evaluated feature of thyroid gland namely the Relations of External branch of superior laryngeal nerve to superior thyroid artery and other anomalies were included in the qualitative data. Sex and side was included in each case.

2. QUANTITATIVE DATA

The quantitative features were entered in master chart and quantified according to their frequency. Tables were used to describe the frequency distribution of each parameter. Appropriate bar diagrams and pie charts were prepared for studying both the study groups (male and female).

STATISTICAL TEST

CHI SQUARE TEST

The chi square test was used to find out whether the observed series of frequency differ between both the study groups (Snedecor & Cochran 1967). The statistical significance or probability was expressed as P value. Statistical analysis was done by using SSP2 (Statistical package for social sciences) programme under the guidance of a statistician.

Results

In all the cases the External laryngeal nerve was found originating from superior laryngeal nerve. It was seen closely related to the superior thyroid artery. The area of crossing of the External branch of superior laryngeal nerve over the superior thyroid artery was classified in accordance with Cernea's classification.

a) In 53% of cases (56% on right and 50% of cases on left) the nerve was crossing the artery less than 1 cm from the upper pole of thyroid gland (Type 2a of Cernea's classification (fig 1)

b) In 34% of cases (32% on right and 36% on left) the nerve was crossing the artery below the upper pole of thyroid gland (Type 2b of Cernea's classification (Fig2)

c) In 13% of cases (12% of cases on right and 14% on left) the nerve was crossing the artery more than 1cm from the upper pole of thyroid gland (Type 1 of Cernea's classification (fig3)

After the crossing the nerve was seen ending by supplying the cricothyroid muscle

Table 1- Variations in the relation of External laryngeal nerve to the superior thyroid artery

Lobe	Type	Male (40)		Female (10)		Total (50)	Statistical
		No	%	No	%		
Right	1	5	12.5	1	10	6	X ² =1.042 Pvalue=0.594
	2a	21	52.5	7	70	28	
	2b	14	35	2	20	16	
Left	1	6	15	1	10	7	X ² =0.518 Pvalue=0.772
	2a	19	47.5	6	60	25	
	2b	15	37.5	3	30	18	

Table 2 - Variations in the relation of External laryngeal nerve to the superior thyroid artery on both sides

Both sides	Type	Total no	Total %
		1	13
	2a	53	53
	2b	34	34

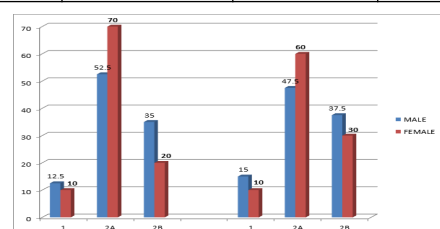


Chart 1- Variations in the relation of External laryngeal nerve to the superior thyroid artery

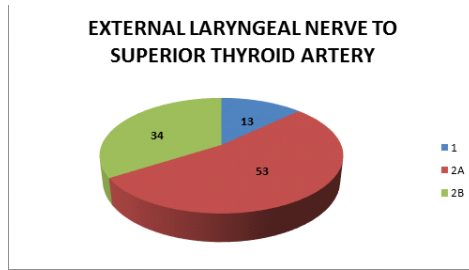


Chart 2- Pie chart showing the relation of External laryngeal nerve to the superior thyroid artery

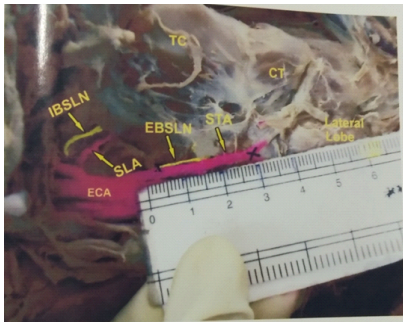


Figure 1- External branch of superior laryngeal nerve(EBSLN) crossing superior thyroid artery(STA) above 1cm from superior pole of thyroid gland-TYPE 1 of Cernea's classification. Upper limit of thyroid gland and the area of crossing over marked as (x).IBSLN=Internal Branch of Superior Laryngeal Nerve, TC=Thyroid cartilage, ECA= External Carotid Artery, CT=Cricothyroid muscle

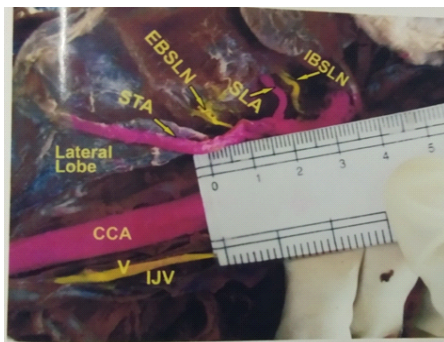

Figure 2-External branch of superior laryngeal nerve (EBSLN) crossing superior thyroid artery (STA) at less than 1cm from superior thyroid pole Type 2a of Cernea's classification. IBSLN=Internal Branch of Superior Laryngeal Nerve, TC=Thyroid cartilage, CCA= Common Carotid Artery, V=Vagus, IJV=Internal jugular vein .SLA=superior laryngeal artery.

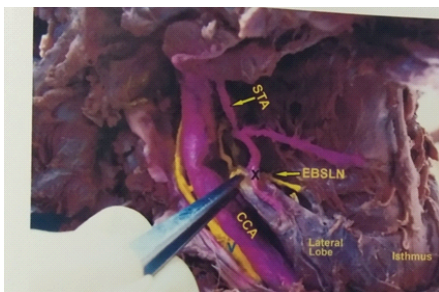

Figure 3- External Branch of superior laryngeal nerve (EBSLN) crossing superior thyroid artery(STA) under the superior pole of thyroid gland.-Type 2b of Cernea's classification. CCA=Common Carotid Artery, V=Vagus.

DISCUSSION

The External branch of superior laryngeal nerve arises in common

with the internal branch of superior laryngeal nerve.it descends deep to superior thyroid artery and then enters the cricothyroid muscle. Several studies have been done both in cadavers and clinical subjects to ascertain the site of the External branch of superior laryngeal nerve crossing the superior thyroid artery in relation to the upper pole of thyroid gland .based on this several classification have been proposed. However, the classification made by cernea is quite popular and is commonly followed by many

NAME OF INVESTIGATOR	RACE	TYPE 1(%)	TYPE 2A (%)	TYPE 2B (%)	TYPE NI (%)
CERNEA	BRAZIL	60	17	20	3
KIERNER	AUSTRIA	42	30	14	13
AINA &HISHAM	MALAY	17.9	61.3	20.8	0
	CHINESE	16.3	53.5	30.2	0
	INDIAN	17.8	44.4	37.8	0
HURTADO LOPEZ	MEXICO	16.7	41.7	35.7	6
BELLANTONE	ITALY	58.6	19.6	10.2	11.6
FURLAN	BRAZIL	47	31	22	0
SEVEN	TURKEY	51.8	37.1	11.1	0
MISHRA	INDIAN	28.2	53.54	10.25	7.69
CHAUNG	CHINESE	16.2	39.5	38.3	6
PRESENT STUDY	INDIAN	13	53	34	0

In the present study, Type 2a was the one more commonly observed.it was noted in53% cases. This incidence is consistent with that reported by Aina and Hisham(2000),Mishra(2007),Lopez(2001) and Chaung(2008).However Cernea(1992),Kierner (1998),Furlan(2003) and Seven (2003) observed Type 1 as the most common type

The next common type observed in the present study was Type 2b in34% of cases, followed by Type 1 in 13% of cases.Aina and Hisham(2000),Lopez(2001) and Chaung(2008) also observed type 2b as the next common type followed by Type 1. No significant difference was observed in males and females

In accordance with the classification of Cernea, it may be noted that the Type 2(type 2a+type2b) is at a greater risk of injury because surgeons handle the vessels within this critical distance of 1cm while performing an adequate thyroidectomy.

NAME OF INVESTIGATOR	NO OF DISSECTION	RISK OF NERVE INJURY%
CERNEA	30	37
KIERNER	52	44
AINA	45	82.2
LOPEZ	84	77.4
BELLATONE	459	29.8
SEVEN	60	54.5
MISHRA	78	63.79
CHAUNG	86	77.8
PRESENT STUDY	50	87

The findings of present study were found consistent with that of Aina and Hisham(2000) Chaung(2008) and Mishra(2007).it may be noted that the risk of nerve injury is high in Indian and Chinese population when compared to the white population.

Anand kumar Mishra (2007) came with observation that accurate dissection of cricothyroid space,skeletonisation and individual ligation of superior thyroid vessels adjacent to the capsule of gland, identification of nerve before ligation of superior pole and use of nerve stimulator or intraoperative neuro-monitoring can decrease the rate of nerve injury.

CONCLUSION

The present work is a gross anatomical study on relation of external branch of superior laryngeal nerve to superior thyroid arteries. 50 thyroid glands were carefully dissected and photographs were taken to document each variation. Charts were prepared for the statistical analysis of the data obtained. The percentage frequencies of each parameter in male and female groups were compared using chi- square test.

The difference in the value between the two study groups was found to be statistically insignificant (P value > 0.05).

External branch of superior laryngeal nerve was classified in accordance with Cernea .In 87% of cases, this nerve was found in close proximity with the upper pole of thyroid gland and therefore at greater risk injury during surgery.

The findings of the present study stress the need for a sound knowledge of common anatomical variations in this region while performing thyroidectomy to avoid complications especially laryngeal nerve injuries

REFERENCES

1. Aina E N and EN Hisham – External laryngeal nerve in thyroid surgery: Recognition and surgical implications, ANZ.J.Surg(2001) 71,212-214
2. AnandKumar Mishra- The External laryngeal nerve in thyroid surgery .the no more neglected nerve.Indian J Med Sc Vol 61, No 1, Jan 2007
3. Bohelto- Relation between the External branch of superior laryngeal nerve and superior thyroid artery: a study in 101 nerves .Rev.Col.Bras.Cir vol 36 no 3 Rio de Janeiro July 2009.
4. Cernea C R ,Ferrar AR,1992a .identification of the External branch of superior laryngeal nerve during thyroidectomy Am J Surg 164:634-639
5. Chaung, Jui- Yo Chen, surgical anatomy of External branches of superior laryngeal nerve in chinese adults and its clinical applications. Arch otolartngo Head Neck Surg/Vol 128, March 2009.
6. D Naidoo,J M Boon,C J Mieny.,P J Becker – Relation of External branches of superior laryngeal nerve to the superior pole of the thyroid gland- An anatomical study- Clin Anat 2007;20(5):516-20
7. Friedman M, Torium DM.2002.Functional identification of the External laryngeal nerve during thyroidectomy .Laryngoscope 96:1291-1292.
8. Kierner. The External branches of superior laryngeal nerve its topographical anatomy as related to surgery of the neck. Arch otolaryngol Head Neck surg. 1998; 124:301-303
9. Lennquist S,Cahlin C,Smeds S.1987.The superior laryngeal nerve in thyroid surgery.Surgery 102:999-1008 as cited by D Naidoo,J M Boon,C J Mieny.,P J Becker – Relation of External branches of superior laryngeal nerve to the superior pole of the thyroid gland- An anatomical study- Clin Anat 2007;20(5):516-20
10. Seven H .2003.The topographical anatomy of the External branches of superior laryngeal nerve and its importance in thyroid surgery: A cadaver study :Kulak Buran Bogaz intis Derg 11:161-165 as cited by D Naidoo,J M Boon,C J Mieny.,P J Becker – Relation of External branches of superior laryngeal nerve to the superior pole of the thyroid gland- An anatomical study- Clin Anat 2007;20(5):516-20
- 11 Thejodhar Pulakunta – Unusual External branch of the superior laryngeal nerve :a case report 2009