



SIMULTANEOUS INSUFFICIENCY FRACTURE OF BILATERAL NECK OF FEMUR WITH COXA VARA

Orthopaedics

Dr. Rishabh Surana

Junior Resident , Department of Orthopedics, Institute of Medical Sciences , Banaras Hindu University, Varanasi , Uttar Pradesh , India – 221005

Professor Saurabh Singh

Professor , Department of Orthopedics, Institute of Medical Sciences , Banaras Hindu University, Varanasi , Uttar Pradesh , India – 221005

Dr. Alok Rai*

Senior Resident , Department of Orthopedics, Institute of Medical Sciences , Banaras Hindu University, Varanasi , Uttar Pradesh , India – 221005. *Corresponding Author

ABSTRACT

Simultaneous insufficiency fracture of bilateral neck of femur with displacement and coxa vara is very uncommon , and very challenging. Osteomalacia is a known cause of insufficiency fracture. We present a case of a young female with non traumatic simultaneous bilateral femur neck fracture. On radiological and laboratory investigation fracture was diagnosed as insufficiency fracture due to osteomalacia with coxa vara. Treatment was done by intertrochanteric valgus osteotomy and fixation by dynamic condylar screw with a prebend plate along with oral and parenteral vitamin D therapy. On six month follow up both side fractures were well united and patient was able to walk without pain with full weight bearing and with normal gait .Her lab investigations also returned to normal during follow up.

KEYWORDS

Insufficiency Fracture, Osteomalacia, Neck Of Femur, Coxa Vara

INTRODUCTION:

Stress fractures are non traumatic fractures. Two factors related to stress fractures are load applied to a bone and mechanical resistance of bone, which indicates bone quality and bone mass. When balance between these two factors get altered a stress fracture arises. On the basis of these two factors, stress fractures can be of two types a) fatigue fractures and b)insufficiency fractures. In fatigue fractures, there is abnormal excessive load on the normal bone which leads to fracture, and in insufficiency fractures mechanical resistance of bone is decreased.¹ Risk factors for insufficiency fractures are those which decrease the mechanical resistance of bone by decreasing bone quality and bone mass, like osteoporosis(senile, postmenopausal ,medicine induced), osteomalacia ,hyperparathyroidism, rheumatoid arthritis and mechanical factors like varus malalignment.² Insufficiency fractures of bilateral neck of femur, simultaneously, is very rare. Insufficiency fractures of neck of femur are generally undisplaced. So here we present a rare case, of displaced Insufficiency fracture of bilateral side of neck of femur with coxa vara in a young female..

Case Report:

A 24 year female presented with inability to walk from one week. On history it was found that patient had groin pain since last three months. On further history it was found that even when patient was pain free she used to walk with waddling type gait. There was no history of trauma or any other prior clinical illness.

On radiological examination, of pelvis with both hip antero-posterior view (figure 1) completely displaced neck of femur fracture was identified with coxa vara on left side (Fullerton & Snowdy type III)³ and undisplaced tension side fracture on right side (Fullerton & Snowdy type II)³.

On laboratory workup(Table1) her serum vitamin D level was 11nmol/lit (range 75-250), calcium level was 8.0mg/dl (range 8.8-10.6), parathyroid hormone level was 200pg/ml(range 18-85), phosphorus level was 2mg/dl(range 2.4-4.4). Other lab investigations, endocrinological profile and rheumatological profile were normal. Her bone mineral density test from lumbar spine was done after fixation of fractures and her T score was – 2.0.

Patient was planned for valgus intertrochanteric osteotomy and fixation by dynamic condylar screw with a prebend plate which was done under spinal anaesthesia (figure 2) . She also received an intramuscular dose of 6lakh IU vitamin D and oral dose of 60,000 IU vitamin D every week. On six month follow up both side fractures were well united(figure 3) and patient was able to walk without pain, with full weight bearing and normal gait .Her lab investigations also returned to normal during follow up.

DISCUSSION:

General causes of insufficiency fractures include osteoporosis, osteomalacia, hyperparathyroidism, rheumatoid arthritis, fluoride treatment, diabetes, Paget's disease, osteogenesis imperfecta and mechanical factors .In our case etiology of fracture was osteomalacia and coxa vara.

Importance of vitamin D in calcium metabolism and bone health has been well known since long.⁴ Persons commonly at risk for vitamin D deficiency include those with inadequate sun exposure, limited oral intake, impaired intestinal absorption. Etiology of osteomalacia are Decreased vitamin D production(Cold weather climates reduce skin sunlight exposure and cutaneous synthesis, Dark skin , Obesity ,elderly),Decreased vitamin D absorption(Nutritional deficiency , Malabsorptive syndromes) Altered vitamin D metabolism(Chronic kidney disease Nephrotic syndrome , Liver disease, Pregnancy) Hypophosphatemia or hypocalcemia, Medications(Antiepileptic drugs, Long-term steroid use).

We established the diagnosis by criteria proposed by Fukumoto et al.,⁵

1. Hypophosphatemia or hypocalcemia
2. High bone alkaline phosphatase
3. Muscle weakness or bone pain
4. Less than 80% BMD of the young-adult-mean
5. Multiple uptake zones by bone scintigraphy or radiographic evidence of Looser zones (pseudofractures)

*Definite osteomalacia defined as all findings.

*Possible osteomalacia defined as having numbers 1, 2, and two of 3,4 or 5 given above.

In vitamin D deficiency serum calcium level will decrease. In response to decrease calcium level Parathyroid hormone will be secreted from parathyroid gland, which will act on bones to balance the serum calcium level by extracting calcium from the bones, osteomalacia will ensue, which further can result in coxa vara and insufficiency fracture. Therefore, in adults, processes that disrupt vitamin D metabolism and its production are at risk for eventually developing osteomalacia and its clinical manifestations.^{6,7}

Malalignment and altered biomechanics of hip can also lead to stress fracture by increased focus of mechanical stress on femur neck.⁸ Carpintero et al ,in his study, analyzed that coxa vara predisposes to femoral neck stress fracture.⁹

Classification of stress fracture of neck femur is given by Fullerton & Snowdy based on both plain radiographs and bone scans, which divides them into 3 groups: Type I fractures, developed on the tension side of the femoral neck ,Type II fractures on the compression side, and

Type III displaced fractures. A fourth category, superiorly based incomplete tension-type fractures, was added later.

Treatment is decided according to the classification .For both Type I, compression-side, undisplaced fractures, and for Type II, incomplete, tension-side fractures, a conservative treatment is indicated, even though, for the latter, a prophylactic surgical fixation is advocated, for Type III surgical treatment is indicated. Various surgical options are available but as our case has coexisting coxa vara, intertrochanteric valgus osteotomy and fixation by dynamic condylar screw with prebend plate was chosen.

To conclude, for treatment of insufficiency fracture due to osteomalacia with coxa vara, along with surgical procedure to correct mechanical alignment reversing of the vitamin D deficiency is equally important. So in our case we did valgus osteotomy and fixation followed by vitamin D deficiency treatment.

quatre observations. *Sem Hôp Paris*1991;67:1755-61.

- Fullerton JR, LeRoy R, Snowdy HA. Femoral neck stress fractures. *The American journal of sports medicine* 16.4(1988): 365-377.
- Holick MF. Vitamin D deficiency. *N Engl J Med*. 2007;357:266-281
- Fukumoto S, Ozono K, Michigami T, Minagawa M, Okazaki R, Sugimoto T, Takeuchi Y, Matsumoto T. Pathogenesis and diagnostic criteria for rickets and osteomalacia--proposal by an expert panel supported by the Ministry of Health, Labour and Welfare, Japan, the Japanese Society for Bone and Mineral Research, and the Japan Endocrine Society. *J Bone Miner. Metab*. 2015 Sep;33(5):467-73.
- Vaishya R, Vijay V, Agarwal AK, Jahangir J. Resurgence of vitamin D: Old wine in new bottle. *J Clin Orthop Trauma*. 2015 Sep;6(3):173-83.
- Rokan Z, Kealey WD. Osteomalacia: a forgotten cause of fractures in the elderly. *BMJ Case Rep*. 2015 Feb 09;2015
- F. Pauwels, *Biomechanics of the Normal and Diseased Hip*, Springer-Verlag, New York, 1976.
- P. Carpintero, et al., Stress fractures of the femoral neck and coxa vara, *Arch.Orthop. Trauma Surg*. 123 (6)(2003)273-277.

Table.1

Investigation	Value	Institutional reference range
Biochemical Bone Profile		
25-Hydroxy Vitamin D (CLIA)(nmol/L)	11.00	75-250
Calcium (total)	08.00	8.80-10.60
Phosphorus	02.00	2.40-4.40
Alkaline phosphate	337.5	30-120
Endocrine Function Test		
Parathyroid hormone (pg/ml)	200	18.5-88.0
LDH, Lactate Dehydrogenase Serum(U/L)	236.0	135-214
Rheumatologic Profile		
Rheumatoid factor	Negative	
ANA	0.35	N<0.8
Anti ds DNA Ab (U/ml)	3.0	N<16.0
Renal Profile		
Creatinine (mg/dl)	0.4	0.51-1.4
Urea (mg/dl)	22	17-43
Calcium , Random Urine(mg/dl)	01	0.50-35.70
Phosphorus ,Random Urine(mg/dl)	8.20	7.00-148.00

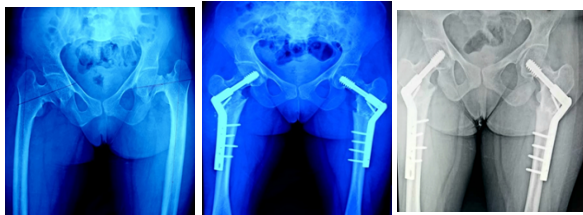


Fig.1 Pre-Op X-ray Pelvis with both Hip showing completely displaced fracture neck of femur with coxa vara on left side(Arrow mark) and undisplaced tension side fracture on right side.

Fig.2 showing immediate post operative procedure of bilateral intertrochanteric valgus osteotomy (Arrow marks) and fixation by dynamic condylar screw with a pre bend

Fig.3 6 month follow-up X-ray Pelvis with both Hip showing union of both the neck fracture and the osteotomy site. Patient started walking with full weight bear and normal gait.

Conflict of interest: none

REFERENCES:

- Daffner RH, Pavlov H. Stress fractures: current concepts. *Am J Radiol* 1992;159:242-5
- Bouquillard E, Marcelli C, Herisson C, Simon L. Les fractures par insuffisance osseuse du bassin et des membres inférieurs : rôle favorisant du fluor. A propos de soixante-