



BALLOON MITRAL VALVULOPLASTY : SIZING THE BALLOON

Cardiology

Dr Deepak R Shejol*

Itape layout chikhli road buldana 443001. *Corresponding Author

Prof Dr. Swaminathan. N

Director, Institute of Cardiology, Madras Medical College, Chennai.

Asst Prof Dr. Tamilselvan

Institute of Cardiology, Madras Medical College, Chennai.

KEYWORDS

BACKGROUND:

The decrease of the incidence of rheumatic heart disease in developed countries had already begun in 1910, and it is now below 1.0 per 100 000. On the other hand, the occurrence rate of rheumatic heart disease in developing countries remains substantial. Because the decline in the prevalence of rheumatic fever in industrialized nations started even before the era of penicillin and thus was related to improved living standards, the continued prevalence of rheumatic heart disease in undeveloped or developing countries is related not only to the limited availability of penicillin but to their socioeconomic status (ie, overpopulation, overcrowding, poverty, and poor access to medical care)(1).

According to the annual report by the World Heart Federation, an estimated 12 million people are currently affected by rheumatic fever and rheumatic heart disease worldwide, and high incidence rates are reported in the Southern Pacific Islands. Several studies were conducted on the prevalence of rheumatic heart disease, reporting 0.14/1000 in Japan, 1.86/1000 in China, 0.5/1000 in Korea, 4.54/1000 in India, and 1.3/1000 in Bangladesh(1).

Percutaneous balloon mitral valvuloplasty (PBMV) is the preferred treatment modality for patients with severe rheumatic mitral stenosis who remain symptomatic despite optimal medical therapy. We hereby evaluated retrospectively 51 patients who underwent PBMV recently in our department.

Before the advent of Percutaneous balloon mitral valvuloplasty (PBMV) the treatment consisted solely of surgical options- Open or Closed commissurotomy and replacement with bio-prosthetic or mechanical prosthesis. Development of devices for PBMV in 1980 and subsequent development in technique has made it the treatment of choice in rheumatic mitral stenosis with favourable valve morphology. The main objective of PBMV is to separate fused commissures, thus reducing transmitral pressure gradient, left atrial pressure, sPAP and increasing mitral valve area and cardiac output. We hereby evaluated retrospectively 51 patients who underwent PBMV recently in our department.

MATERIALS AND METHODS:

Rheumatic mitral stenosis patients who underwent PBMV were included in this study. Data from 51 patients was retrospectively analyzed with respect to age, sex, height, weight, Balloon size, dilations given, mean LA pressure fall post procedure and Mitral regurgitation.

Procedure :

The Inoue Balloon catheter was used in this study (Toray, Tokyo, Japan). The balloon size is pressure dependent and consists of 3 portions with slightly different compliance. As pressure is gradually added, the distal portion of the balloon inflates first, followed by the proximal portion. The unique part of the Inoue balloon is its middle waist portion that has the least pressure compliance, with which fixation of the balloon catheter is facilitated and the degenerated fused commissure(s) can be dilated substantially.

The procedure was performed via a femoral approach with a 9F sheath

in the vein and a 5F sheath in the artery, with the patient under light sedation. After bolus administration of 1000 U heparin, right heart catheterization was performed. Right atrigraphy is then performed to determine the septal puncture site for the Brockenbrough needle. Transseptal catheterization was performed via a standard Brockenbrough procedure using anteroposterior & lateral views. While slowly withdrawing the Brockenbrough catheter from superior vena cava into the interatrial septum, the Brockenbrough Needle was advanced beyond the interatrial septum when the tip of the catheter falls into the fossa ovalis. Transesophageal echocardiography was useful in identifying the anatomic location of the interatrial septum relative to the right atrium. After advancing the Brockenbrough needle, a coiled-tip guidewire was placed into the left atrium through the mullins sheath. Then 4000 U of heparin was given to reduce the risk of a thromboembolic event during the manipulation of catheters and wires in the left atrium. (2)

In the next step, the Inoue balloon catheter is advanced over the coiled-tip wire. Once the balloon catheter has crossed the interatrial septum, the catheter was placed in the left atrium so that the catheter forms a loop with the tip facing toward the mitral valve orifice. The tip of the balloon was inflated with 1 to 2 mL of contrast media, allowing blood flow to direct the balloon tip into the left ventricle.

If advancement of the Inoue balloon proved difficult, the stylet was inserted in the balloon catheter, and the balloon catheter with stylet were moved together towards the mitral valve orifice. With the right anterior oblique view, which helps identify the proper line between the base and the apex, the deflated Inoue balloon catheter was advanced until the tip of the catheter has crossed the mitral valve into the left ventricle. Once the balloon catheter has been inserted into the left ventricle, the distal portion of the balloon was inflated with contrast media using a specially graduated syringe. The catheter was then pulled until resistance is felt and dilation was done.

After dilatation, the left atrial pressure and the left ventricular were obtained. If the pressure gradient between the left atrial pressure and the simultaneously obtained left ventricular pressure does not decrease, the balloon size was increased in 1-mm increments until the pressure gradient decreases or substantial worsening of mitral regurgitation occurs. In addition, 2-dimensional echocardiographic observations were performed after each dilatation. To assess mitral valve orifice area after each dilatation, planimetry of the valve orifice with 2-dimensional echocardiography was performed.(1)

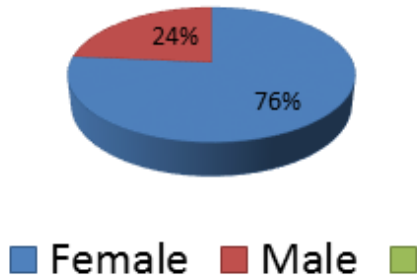
For statistical analysis we divided the patients (n=51), in two groups Group 1 (n=15) who underwent PBMV according to standard formula for balloon size $[0.1 * \text{height}(\text{cm}) + 10]$ and Group 2 (n=36) who underwent PBMV with balloon that was 1.1 + 0.5 mm undersized to the standard formula value.

RESULTS :

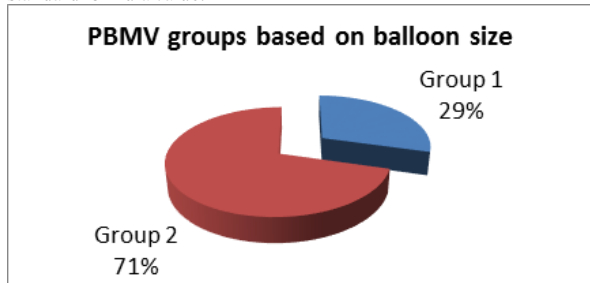
Retrospective analysis of 51 patients who underwent PBMV recently showed : Male to female ratio of 1:3 (Female- 39, male-12).

The minimum age of patient was 14 yrs and maximum age was 52 yrs

with a mean age of 35 yrs.



For statistical analysis we divided the patients (n=51), in two groups Group 1 (n=15) who underwent PBMV according to standard formula for balloon size $[0.1 * \text{height}(\text{cm}) + 10]$ and Group 2 (n=36) who underwent PBMV with balloon that was $1.1 + 0.5$ mm undersized to the standard formula value.



Mean height of patient in this study was $154 + 9$ cm. Single balloon technique was used in all the patients. Average Wilkins score was 6 ± 2 .

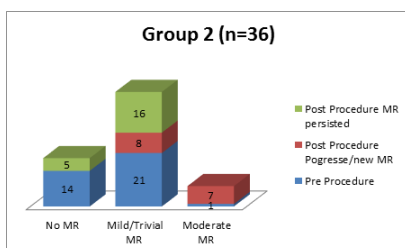
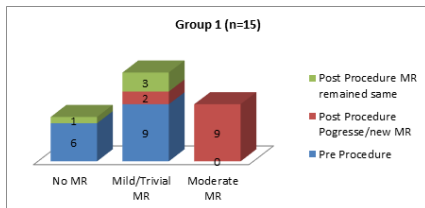
Table 1. Wilkins Score

Grade	Mobility	Thickening	Calcification	Subvalvular Thickening
1	Highly mobile with only leaflet tips restricted	Leaflets near normal in thickness (4-5 mm)	A single area of increased echo brightness	Minimal thickening just below the mitral leaflets
2	Leaflet mid portions and base portions have normal mobility	Middleleaflets normal, considerable thickening of margins (5-8 mm)	Scattered areas of brightness confined to leaflet margins	Thickening of chordal structures extending to one of the chordal length
3	Valve continues to move forward in diastole, mainly from the base	Thickening extending through the entire leaflets (5-8 mm)	Brightness extending into the mid portions of the leaflets	Thickening extended to distal third of the chords
4	No or minimal forward movement of the leaflets in diastole	Considerable thickening of all leaflet tissue (~8-10 mm)	Extensive brightness throughout much of the leaflet tissue	Extensive thickening and shortening of all chordal structures extending down to the papillary muscle

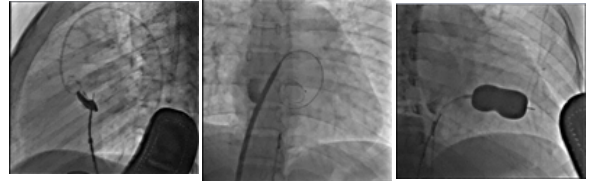Adapted from Wilkins et al¹⁷ with permission from BMJ Publishing Group Ltd. Copyright 1988 BMJ Publishing Group Ltd and British Cardiovascular Society.

The mean balloon size using standard formula $[0.1 * \text{height}(\text{cm}) + 10]$ was $25.2 + 2$ mm This size of balloon was selected in 29 % (n =15) patients was according to this formula. Among these No Baseline MR was present in 40% patients (n=6), Trivial/mild MR was present in 60% (n=9). Post procedure, these Patients, 60% (n=9) patients had moderate MR 2+.

In rest of the 71 % (n=36) patients the balloon was $1.1 + 0.5$ mm undersized to the above formula. In this group Baseline no MR was found in 39% (n=14), Trivial to Mild MR was present in 58% (n=21) and Moderate MR was present in 3% (n=1) patients. In these Patients, 19 % (n=7) patients had moderate MR 2+ post procedure. This was however statistically not significant between the two groups with 95% confidence interval (fisher exact test $p = 0.06$).



Average fluoroscopy time was $6.1 + 2.5$ minutes. 68% patients required single dilatation where as 22 % required 2 or more dilatations of the balloon. Mean left atrial pressure dropped from $26 + 6$ to $14 + 5$ mm Hg and mitral valve area increased from $0.8 + 0.4$ to $1.65 + .03 \text{cm}^2$. None of them had severe mitral regurgitation. Serious complications like tamponade, CVA, death Didn't occur in our study.



CONCLUSION:

Balloon mitral commissurotomy is relatively safe and very effective in treating patients with severe symptomatic mitral stenosis as it provides immediate clinical and hemodynamic improvement. The size of balloon selected by standard formula in Indian subset seemed to increase the incidence of more than mild mitral regurgitation by three fold. Under sizing the balloon by 1 mm decreased the incidence of this complication by 2/3 fold without affecting the end result. This was however statistically not significant. A study on a larger scale will give us better insight into this finding.

REFERENCES:

1. Nobuyoshi M, Arita T, Shirai S ichi, Hamasaki N, Yokoi H, Iwabuchi M, et al. Percutaneous balloon mitral valvuloplasty: a review. Circulation. 2009;119(8).
2. Hung JS. Atrial septal puncture technique in percutaneous transvenous mitral commissurotomy: Mitral valvuloplasty using the Inoue balloon catheter technique. Cathet Cardiovasc Diagn. 1992;26(4):275-84.
3. Percutaneous Balloon Mitral Valvuloplasty in Comparison With Open Mitral Valve Commissurotomy for Mitral Stenosis During Pregnancy ; Jose' A. M. de Souza, MD, Eulogio E. Martinez, Jr, MD, John A. Ambrose, MD, FACC, Claudia M. R. Alves, MD, Daniel Born, MD, EnioBuffolo, MD, Antonio C. C. Carvalho, MDJACC Vol. 37, No. 3, 2001 March 1, 2001:900-3
4. Mitral valve disease: Advances in catheter interventions, CN Manjunath, Prabhavathi, Medicine Update 2010 Vol. 20