



NONSURGICAL MANAGEMENT OF PERIAPICAL LESION USING CALCIUM SILICATE BASED CEMENTS AND SEALER FOLLOWED BY WALKING BLEACH TO MANAGE INTRINSIC DISCOLORATION OF TOOTH – 2 CASE REPORTS

Dental Science

Dr Shilpi Tiwari* PG student, Department Of Conservative Dentistry and Endodontics, Vokkaligara Sangha Dental College & Hospital, Bangalore, India. *Corresponding Author

Dr Meena Naganath MDS, Professor, Department Of Conservative Dentistry and Endodontics, Vokkaligara Sangha Dental College & Hospital, Bangalore, India.

ABSTRACT

Microbial infection of pulpal tissues leads to a periapical lesion. The main objective involved in the treatment of these cases is to get rid of microorganisms and its toxins from the root canal as well as from the periapical region followed by the restoration of tooth function. An immature tooth with pulpal necrosis and periapical pathology presents a great challenge to an endodontist. These cases should be treated with conventional apexification procedure with and without apical barriers. Calcium hydroxide is the most commonly used material in apexification procedure, however they have some disadvantages. Hence the use of calcium silicate based cements like mineral trioxide aggregate (MTA) and Biodentine has been proposed in literature.

KEYWORDS

Apexification, Calcium hydroxide, MTA, Fillapex sealer, Walking bleach

INTRODUCTION :

Dental caries is an infectious microbial disease which invades the dental pulp and its progression leads to a periapical lesion. Hence periapical lesions are the sequel of dental caries and more than 90% of these periapical lesions includes either a periapical granuloma, periapical abscess or a radicular cyst.¹ These cases are usually diagnosed accidentally on a radiograph of a nonvital tooth or following acute dental pain. The main objective involved in the treatment of these cases is to get rid of microorganisms and its toxins from the root canal as well as from the periapical region followed by the restoration of tooth function.² There are two different approaches to manage these periapical lesions – first is nonsurgical endodontic approach i.e. conservative orthograde approach and second is more invasive surgical approach. All cases should initially be treated with nonsurgical approach, however some cases which don't respond to nonsurgical approach should manage with the surgical approach. Hence the surgical therapy should be the last resort to manage periapical lesions.³

Necrotic teeth with open apices often presents with the challenges like overfilling due to absence of apical stop, hence these cases has to be treated with “Apexification” procedure in which apical third of canal should be filled with a biocompatible material followed by backfilling with thermoplastisized gutta percha. Calcium hydroxide is the most commonly used material in apexification procedure, however they have some disadvantages like long term use can affects the mechanical properties of dentin, required multiple visit treatment and the risk of root canal contamination by microbial coronal leakage and unpredictable outcome. Hence to overcome these problems associated with CH, the use of calcium silicate based cements (CSC) like mineral trioxide aggregate (MTA) and Biodentine has been proposed.⁴

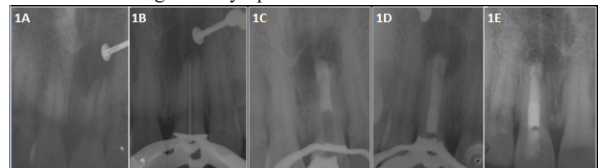
The present case report discusses a successful nonsurgical management of two cases using MTA cement and sealer with 1 year follow up and also discusses the management of intrinsic discoloration by walking bleach.

CASE REPORT

Case 1:

A 39 years old female patient presented to Department of Conservative Dentistry and Endodontics with the chief complaint of pain in front teeth region since 3 days. Patient also had a history of trauma in her childhood. Clinical examination revealed a slight discolored maxillary left central incisor without any fracture in crown along with a draining sinus in relation to #21. Tooth was tender on percussion and showed no response on cold test and electric pulp tester as compare to contralateral tooth. Intraoral periapical radiographic (IOPA) showed a periapical radiolucency of around 0.5x1cm involving the apex of #21 with immature root apex (fig 1a). Hence a provisional diagnosis of class 4 Ellis fracture with chronic periapical abscess was made in relation to 21. Apexification with an apical barrier of MTA followed by thermoplastisized Gutta-percha obturation was planned.

Tooth was isolate with rubber dam (Hygenic –Coltene) and endodontic access was done in #21 and radiograph was taken to confirm the working length. Gentle instrumentation was done with #80 K-file and irrigation was done thoroughly with 3% Sodium hypochlorite during shaping and cleaning procedure. Canal was dried with paper points and metapex (MetaBiomed) was given as an intracanal medicament for 1 week and tooth was temporized with cavit (3M EPSE). Patient became asymptomatic after 1 week recall, hence metapex was removed by flushing with normal saline and the final irrigation was done with 3% NaOCl followed by 17% EDTA solution. Irrigant activation was performed with EndoActivator (Dentsply). Finally the canals were dried and MTA ANGELUS powder was mixed with distilled water and plugged into the apical 5 mm of canal using MTA carrier under microscope, then a moistened cotton was placed into the canal and patient recalled after 24 hours. On her next visit, remaining canal was backfilled with thermoplastisized Gutta-percha obturation technique using CALAMUS (Dentsply) and MTA fillapex sealer (Angelus) (fig 1B-D). Patient was not willing for further bleaching procedure, hence access filling was done with composite resin. 1 year follow up radiograph (fig 1H) showed complete resolution of periapical lesion with no clinical signs and symptoms.

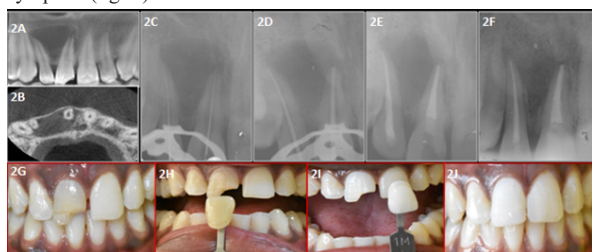


Case 2 :

A 21 years old male patient presented to Department of Conservative Dentistry and Endodontics with the chief complaint of pain front teeth region since 10 days. Patient had a history of trauma 12 years back. Clinical examination revealed a discolored maxillary right central incisor with Ellis class 2 fracture. #11 and 12 were tender on percussion and showed no response on cold test and electric pulp tester as compare to contralateral tooth. Intraoral periapical radiographic (IOPA) showed a large periapical radiolucency of around 3x3cm involving the apex of #11 and #12 (fig 2A-B). Hence a provisional diagnosis of symptomatic apical periodontitis was made for both teeth. The treatment planned was to perform nonsurgical endodontic treatment of both involved teeth followed by walking bleach of #11.

Teeth of interest were isolate with rubber dam and endodontic access was made. The working length of both canals were initially determined by apex locator (ROOT ZX II, J Morita) and then verified by IOPA. The biomechanical preparation was done using step back technique and irrigation was done thoroughly with 3% Sodium hypochlorite during shaping and cleaning procedure. Metapex (MetaBiomed) was given as an intracanal medicament for 1 week and tooth was temporized with cavit (3M EPSE). After 1 week recall metapex was removed by flushing with normal saline and the final irrigation was done with 3% NaOCl followed by 17% EDTA solution. Irrigant activation was

performed with EndoActivator (Dentsply). Finally the obturation was completed using gutta percha and MTA fillapex sealer and temporary filling was given and patient recalled after 1 week (fig2C-2E). On next visit temporary filling was removed followed by GP removal 2 mm beyond CEJ and then resin modified glass ionomer cement (RMGIC - Fuji) was placed till the orifice level in a bobsled tunnel shape. Now chamber was etched with 37% phosphoric acid for 30seconds and then washed and dried followed by placement of mixture of sodium perborate and 30% hydrogen peroxide. Finally a cotton pellet moistened with hydrogen peroxide was placed and patient recalled after 1 week. Dressing was changed weekly and desired shade was achieved in 3 visits. Finally the access filling was done with composite resin along with the restoration of Ellis class 2 fracture with putty index method (fig2G-2J). 1 year follow up radiograph showed complete resolution of periapical lesion with no clinical sign and symptom (fig2F).



DISCUSSION:

Periapical lesions are the sequel of pulpal infections and the progression of these lesions results in periapical inflammation and resorption of hard tissues. The successful endodontic therapy is dependent on a hermetic seal at the apical region as well as coronally to prevent the reinfection of pulpal space. The endodontic treatment of nonvital immature anterior teeth after trauma remains complicated because of large open apices and thin dentinal walls. Hence apexification is a treatment of choice in such cases.^{4,6} Apexification is the process of creating a apical barrier with hard tissue at the root end using a biocompatible material. In the past calcium hydroxide was most commonly used in apexification, however it has some drawbacks like longer treatment time, need multiple visits and unpredictable outcomes, hence to overcome these limitations of calcium hydroxide, single visit apexification using MTA was introduced. MTA has an alkaline pH(12.5) which provides a favorable environment for cementum deposition at the root apex and they are less cytotoxic than CH.⁷ Hence in the case 1, MTA apexification was done. MTA Fillapex is an bioceramic sealer which offers several advantages i.e presence of calcium ions in this sealers enables regeneration of the bone and periodontal tissues and being hydrophilic in nature, moisture sorption from the canal promotes a sealer expansion which improves the sealing ability of sealer.⁷ Hence in the present case report 2, MTA sealer was used with conventional gutta percha.

Tooth discoloration can be intrinsic and extrinsic. There are several local factors which causes intrinsic discoloration- trauma, loss of vitality, endodontic treatment and restorative procedures. There are several approaches to manage these discoloration like bleaching, veneers, laminates, crowns etc, however nonvital bleaching is a minimally invasive approach for esthetic rehabilitation of a non vital discolored tooth. Most commonly used bleaching agent in nonvital bleaching is sodium perborate alone or in combination of sodium perborate with hydrogen peroxide which is more effective. Hence in case 2 sodium perborate with 30% hydrogen peroxide was given. At home bleaching in a nonvital teeth is also known as "Walking bleach".⁹

A good cervical barrier is necessary to prevent the diffusion of bleaching agents to avoid undesirable post-operative complications and the shape of this barrier should be as "bobsled tunnel" when viewed from facial aspect to block the dentinal tubules at the cervical region to prevent the external cervical resorption. Resin modified glass ionomer cement is preferred over conventional GIC because RMGIC is a light cure material hence bleaching procedure can be start from the same appointment, on the other hand conventional GIC takes approximately 24 hours to set, hence bleaching procedure can be done in next visit i.e after 24 hours.⁹ Hence in case 2 resin modified glass ionomer cement (RMGIC) was given as a cervical barrier.

REFERENCES:

1. Mutluay AT, Mutluay M. Management of large periapical lesion due to trauma using triple antibiotic paste. *Journal of Oral and Maxillofacial Radiology*. 2017 May 1;5(2):58.
2. Varghese LJ, Haridas AK, Mubasheer M, Kurian SD, Naveen OP, Peter CD. Surgical and

3. Non-surgical Intervention for the Management of Radicular Cyst-A Comparative Study. Prasanthi NN, Chittem J, Simpsy GS, Sajjan GS. Surgical management of a large inflammatory periapical lesion with platelet-rich fibrin. *Journal of Interdisciplinary Dentistry*. 2017 May 1;7(2):76.
4. Narang K, Nayak M, Wahed A, George JV, Mathew S. Management of Non-Vital Teeth with Open Apices using MTA: Two Case Reports. *Journal of Dental and Orofacial Research*. 2018;14(1):75-9.
5. Vitti RP, Prati C, Silva EJ, Sinhoreti MA, Zanchi CH, e Silva MG, Ogliari FA, Piva E, Gandolfi MG. Physical properties of MTA Fillapex sealer. *Journal of endodontics*. 2013 Jul 1;39(7):915-8.
6. Magro MG, Kuga MC, Ricci WA, Keine KC, Tonetto MR, Lima SL, Borges AH, Belizário LG, Bandeca MC. Endodontic Management of Open Apex Teeth Using Lyophilized Collagen Sponge and MTA Cement: Report of Two Cases. *Iranian endodontic journal*. 2017;12(2):248.
7. Jain JK, Ajagannavar SL, Jayasheel A, Bali PK, Jain CJ. Management of a fractured nonvital tooth with open apex using mineral trioxide aggregate as an apical plug. *International Journal of Oral Health Sciences*. 2017 Jan 1;7(1):44.
8. Khetarpal A, Chaudhry S, Talwar S, Verma M. Endodontic management of open apex using MTA and platelet-rich fibrin membrane barrier: A newer matrix concept. *Journal of clinical and experimental dentistry*. 2013 Dec;5(5):e291.
9. Pandey SH, Patni PM, Jain P, Chaturvedi A. Management of intrinsic discoloration using walking bleach technique in maxillary central incisors. *Clujul Medical*. 2018;91(2):229.