



STUDY AND REVIEW OF THE VARIATION IN COELIAC TRUNK AND ITS BRANCHING PATTERN

Anatomy

Dr. Lalan Prasad Sah

Junior Resident Deptt of Anatomy DMCH Darbhanga, Laheriasarai.

Dr. Sweta Rani

Junior Resident Deptt of Anatomy DMCH Darbhanga, Laheriasarai.

Dr. Manish Kumar

Junior Resident Deptt of Anatomy DMCH Darbhanga, Laheriasarai.

Dr. G.S.Jha*

Assistant Prof. Deptt of Anatomy DMCH Darbhanga, Laheriasarai. *Corresponding Author

Dr.S.K.Karn

Associate prof. Deptt of Anatomy DMCH Darbhanga, Laheriasarai.

ABSTRACT

Background: coeliac trunk is the ventral branch from abdominal aorta which supplies to the Stomach ,spleen,liver,and gall bladder. The anatomical knowledge about variation Of coelick trunk and its branches is important for surgeons and radiologists.

Materials And Methods: The study is conducted in Deptt of Anatomy DMCH, Darbhanga, 35 well preserved cadavers were used for the study. Cadavers are dissected properly to visualize the coeliac trunk and branches.

Results: The mean lenth of coeliac trunk was 4.8 mm and the mean diameter was 5.2mm. observation was done on the branching pattern of coeliac trunk, collateral branches,bifurcation and trifurcation.

Conclusion: Several author have been studied deeply all aspects of coeliac trunk, its branches and variations and one should be updated from time to time.

KEYWORDS

Coeliac Trunk, Common Hepatic Artery

INTRODUCTION :

The Vascular anomalies are quite frequently observed in coeliac trunk, also in the vessels forming circle of willis and renal arteries. The vascular abnormalities in the upper and lower limbs may go unnoticed for a life time, but in case of variations in great blood vessels of abdomen, it certainly needs attention because of their surgical importance(1).

Current study is focused on branching pattern of coeliac trunk and its variations. The arteries of the upper abdomen have been gone for surgical intervention frequently in cases of oesophageal cancer, carcinoma of the stomach, resection of tumours in head of pancreas, and the surgeries like oesophagectomy, total gastrectomy and colonic interposition(2). The Coeliac trunk is the first ventral branch of abdominal aorta at the level of the 12th thoracic vertebra. Its branches namely left gastric artery (LGA), common hepatic artery (CHA) and splenic artery (SA) supply the primary organs namely the stomach, pancreas, spleen, liver and the duodenum till the opening of Bile duct(3).

The Left gastric artery is a small branch from the coeliac trunk, it gives multiple branches that run onto the anterior and posterior surfaces of the stomach and anastomoses with the right gastric artery in the region of the incisura angularis. It gives small oesophageal branch which supplies abdominal part of oesophagus also. The Common hepatic artery gives three branches, which are right gastric artery, gastro duodenal artery and then it continued as the hepatic artery proper. The Gastro duodenal artery gives branches named as right gastro epiploic artery and superior pancreatico - duodenal artery. The splenic artery is the largest branch of coeliac trunk, which is tortuous in nature and runs behind the stomach and further it proceeds toward the hilum of spleen. During its long course, it also gives short gastric branches, left gastroepiploic artery, and numerous small arteries which supplies to the pancreas(3, 4).

Many authors has been studied on branching pattern of Coeliac trunk and reported number of variations such as Bifurcation of Coeliac trunk as Gastrosplenic and common hepatic artery, trifurcation of coeliac trunk as left gastric, common hepatic and splenic arteries, variation in origin of common hepatic artery as a direct branch from abdominal aorta, origin of left hepatic artery from the gastro-duodenal artery and some rare variations like combined origin of coeliac trunk and superior mesenteric artery. Such variations in the branching pattern of the coeliac trunk may predispose to iatrogenic injury during surgical procedures such as total pancreatectomy and resection of tumours in

head of pancreas. The anatomical knowledge on variations of coeliac trunk may be useful in planning and executing the surgical procedures in the upper abdomen(5). Present study is investigated in Bihar, region population and the anatomical updates mainly focused on the coeliac trunk and its three branches. This kind of study may be helpful to Vascular Surgeons, Gastroenterologists, Hepatologists as well as Radiologists in their routine clinical practice.

The aim of this study was to study the anatomy of coeliac trunk and its branches, and providing a wide range of information regarding branching pattern of coeliac trunk and its variations.

MATERIAL AND METHODS :

Study Site-A total of 35 adult cadavers dissected for the present study in the Department of Anatomy, Darbhanga medical college and hospital Laheriasarai. Out of thirty five cadavers, there were twenty six male and nine female bodies. The cadavers have been collected from various regions in Bihar state. Cadavers were dissected according to the procedure described in the standard anatomical dissection manuals and thoroughly verified. All variations are photographed to illustrate the results of the present study.

RESULTS:

Thirty five well preserved cadavers were dissected in the department of Anatomy DMCH, during dissections of undergraduate students. Out of thirty five bodies only nine were female cadavers and the remaining twenty six were male cadavers. The coeliac trunk and its branches were well exposed, traced and photographed where ever required, the variations were noted and analysed.

Length of Coeliac trunk: It is measured from its origin up to the emission of the first branch; it may be Left Gastric Artery or Splenic Artery or Common Hepatic Artery. The mean length of coeliac trunk was 4.8 mm and range between 3-10 mm.

Diameter of Coeliac trunk: The range of diameter was mostly between 0.8-12mm and the mean diameter was 5.2 mm.

Branching pattern of coeliac trunk: Observation was done on branching pattern of coeliac trunk.

Classical type (Fig. No 1) of branching pattern was observed in 14 specimens (40%) out of 35. in this type the Coeliac trunk gives the left gastric, Common hepatic and Splenic Artery in order of sequence.

a). Bifurcation (Fig. No 2) of Coeliac Trunk was seen in three

specimens (8.6%), Coeliac Trunk was bifurcating as Common Hepatic and Gastro splenic arteries later the Gastro splenic artery divided into Left Gastric Artery and Splenic artery.

b). Trifurcation (Fig. No 3) of Coeliac trunk was seen

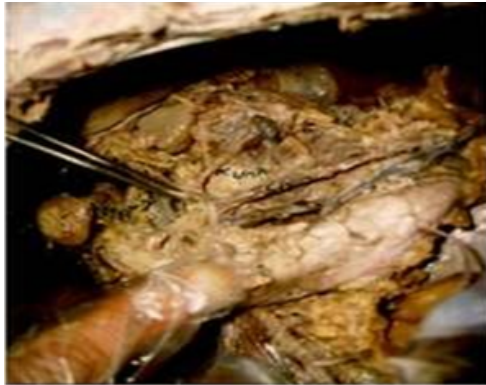

Fig 1 : Coeliac Trunk - Classical Type Of Branching

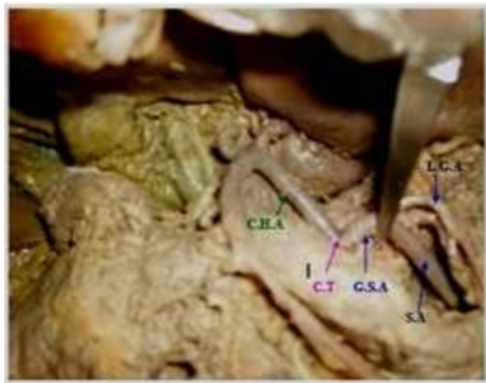


Fig 2 : Bifurcation Of Coeliac Trunk Showing Gastro Splenic & Common Hepatic Artery

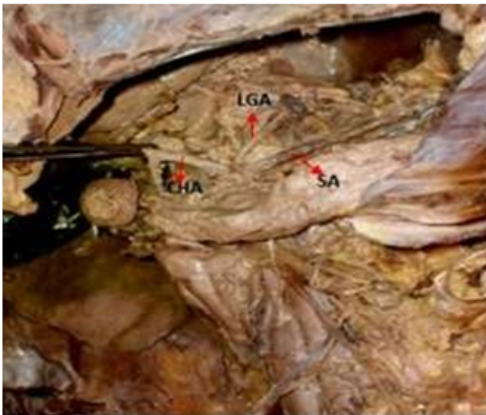


Fig 3 : Trifurcation - Classical Type Haller's Tripod Seen

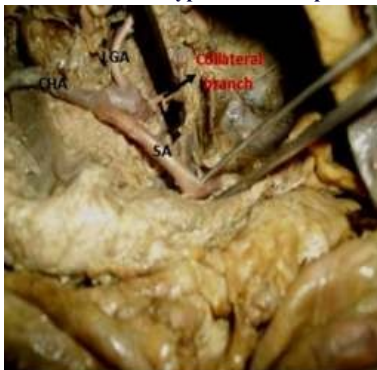

Fig 4 : Coeliac Trunk - Showing Collateral Branch

in 16 cases (45.7%) out of 35 bodies. In this the Left gastric, common hepatic and splenic arteries are trifurcating at the same level forming Haller's tripod.

d)Coeliac Trunk showing collateral branch (Fig. No 4) was observed in 2 cases other than the left gastric, common hepatic and splenic branches (5.7%).

e)Coeliaco-mesenteric trunk: Combined origin of Coeliac Trunk and superior mesenteric artery is referred as Coeliaco-mesenteric trunk. Unfortunately we could not found such kind of variation in present study.

DISCUSSION :

Observations of the present study revealed that the coeliac trunk was seen as the first branch of abdominal aorta just below the aortic opening of the diaphragm in all thirty five cadavers. According to Hiatt et al(5) the range of length was from 5 to 40 mm, Varma K(6) recorded mean length of Coeliac trunk was 10mm, Sh vedav chenko (7) recorded the length of Coeliac trunk varied between 10-15mm, and Sridhar Varma K et al (6) reported mean length of Coeliac trunk was 12mm. Present study revealed that the mean length was 4.8mm and the range was 3-10mm. Results also revealed the diameter of coeliac trunk in present study were almost similar to the older studies reported by Sh vedav chenko (7) and Van Damme and Bonte.

Present study revealed bifurcation of coeliac trunk in 3 (8.6%) cases. Similar studies reported by Sridhar Varma K(6) in 5.5% cases and Sh Vedav chenko et al(7) reported it was 5%. Present study also shows that the coeliac trunk was trifurcated in 45.7% of cases. Findings of current study were almost similar to the studies conducted by Sh vedav chenko et al(7) it was 52.8%. Present study shows collateral branches arising from Coeliac Trunk in 2 (5.7%) cases. Van Damme J.P(9), Ucerler H, Rawat K. S and Petrell S reported almost similar variation in their literature.

Several authors have been studied deeply in all aspects of coeliac trunk and its branches and variations but even then one should be updated from time to time.

The anatomical Knowledge on Coeliac trunk and its branching pattern and common variations has important clinical significance in an abdominal operation or invasive arterial procedure especially in liver transplantation, Laparoscopic surgery and radiological procedures.

REFERENCE:

- Allen PJ, Stojadinovic A, Ben-Porat L, Gonen M, Kooby D, Blumgart L, Paty P, Fongy. The management of variant arterial anatomy during hepatic arterial infusion pump placement, *Ann surg Oncol.* 9(3):875- 880, 2002.
- Charbon GA, Anderson MF. Hepatic hemodynamics as related to blood flow through gut, spleen, and pancreas. *Gut*, 30(2):265-78, 1989.
- Susan Standring. *Gray's Anatomy, Anatomical basis of Clinical practice*, 40th edition. Elsevier Churchill Livingstone: New York, 1073, 2008.
- Matsuki M. Preoperative assessment of vascular anatomy around the stomach by 3D imaging using MDCT before laparoscopy-assisted gastrectomy. *Am. J. Roentgenol*, 183(1): 145-51, 2004.
- Hiatt JR, Gabbay J, Busuttill RW. *Surgical anatomy of the hepatic arteries in 1000 cases.* *Ann. Surg.* 220(1):50-2, 1994.
- Sridhar Varma K, Pamidi N, Vollala VR, Bolla SR : Hepato-spleno-mesenteric trunk: a case report. *Rom J Morphol Embryol* 2010; 5(1):401-402.
- Sh Vedav Chenko AI. Anatomic features of the celiac trunk. *Rom J Morphol Embryol* 120(5):62-65, 2001.
- Van Damme JP, Bonte J. *Vascular anatomy in abdominal surgery.* Stuttgart, Thieme, pp 27-86, 1990.
- Van Damme JP, Bonte J. The branches of the celiac trunk *Acta Anat.* 122(2):110-114, 1985.
- Ucerler H, Asli A. Multiplicity of the variations in the ventral branches of abdominal aorta. *Ital. J Anat. Embryol.* 111(1):15-22, 2001.
- Rawat KS. CT angiography in evaluation of vascular anatomy and prevalence of vascular variations in upper abdomen in branch variants. *Ind J Radiol Imaging.* 16: 457-481, 2005.
- Petrell S, Rodriguez C. Origin of inferior phrenic arteries in the celiac trunk. *Int. J. Morphol.* 24(2):275-8, 2006.