



RETROSPECTIVE STUDY OF RECURRENT PHYLLODES TUMORS AND ASSESSMENT OF THE ROLE OF ADJUVANT RADIOTHERAPY TO REDUCE THE RECURRENCE FURTHER.

General Surgery

Dr. Suman De* Junior Resident, Department of General Surgery, Nilratan Sircar Medical College & Hospital, Kolkata. *Corresponding Author

Dr. Nirjhar Bhattacharya Professor, Department of General Surgery, Nilratan Sircar Medical College & Hospital, Kolkata.

ABSTRACT

Background: Phyllodes tumors (PTs) are rare biphasic fibroepithelial neoplasms accounting for < 1% of all breast lesions[1].

Aim: To reduce the recurrence rate of phyllodes tumor of breast.

Materials And Methods: A retrospective study which reviewed the recurrent phyllodes tumors for last 10 yrs in our hospital.

Results: We found that out of 14 patients, all underwent radical surgery. 9 patients (64%) received post operative radiotherapy after radical surgery. After a follow up period of 1- 2 yrs. only 1 patient (11%) develops local recurrence, among the post radiotherapy group. In the non irradiated group of 5(36%), 3 patients (60%) develop local recurrence.

Conclusion: The study reflects that radiotherapy following radical surgery reduce the recurrence rate.

KEYWORDS

Breast, Recurrent Phyllodes Tumor , Adjuvant Radiotherapy.

INTRODUCTION

Phyllodes tumors (PTs) are rare biphasic fibroepithelial neoplasms accounting for < 1% of all breast lesions^[1]. The least aggressive form may behave similar to fibroadenomas, yet with a high local recurrence rate if excised without wide margins, while its malignant form can give distant metastasis^[2,3]. Typically, PTs present as a palpable breast lump and were traditionally differentiated from FAs based on their larger size at presentation.

However, with increased breast awareness and screening programmes, smaller and incidental lesions are being treated of phyllodes tumors remains surgical excision. Wide local excision, with a margin of at least 1 cm found on imaging^[4]. In symptomatic breast clinics, including this institution, "triple assessment" consisting an initial physical examination, followed by radiological imaging (ultrasound and/or mammography) and histological sampling either by fine-needle aspiration cytology (FNAC) or core biopsy is the standard diagnostic pathway for palpable breast lesions.

The purpose of triple assessment is to provide a more accurate pre-operative diagnosis to ensure proper surgical planning and avoiding re-excision or tumor recurrence^[5]. PT have an increased potential for local recurrence, even if histologically benign, and some may follow a malignant course. Local recurrence rates of up to 20%, even for benign PT, have been reported^[6-9].

The main treatment of phyllodes tumors remains surgical excision. Wide local excision, with a margin of at least 1 cm is the most effective surgery^[10,11].

Adjuvant radiotherapy (RT) for phyllodes tumors is controversial. Radiotherapy is unnecessary for benign phyllodes tumors that are widely excised.

AIM

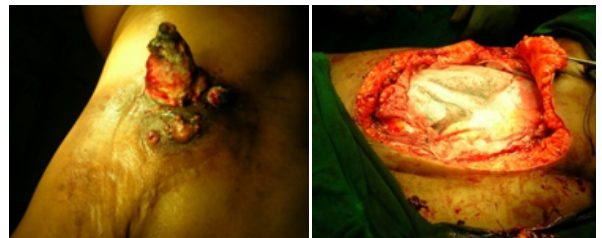To reduce the recurrence rate of the phyllodes tumors of breast.

OBJECTIVES

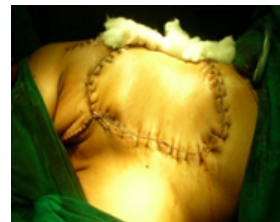- Roll of radical surgery to reduce the chance of recurrence.
- Role of adjuvant radiotherapy to increase the disease free interval / cure.

METHODS

Retrospective study of recurrent phyllodes tumors, managed in our hospital for last 10 yrs. All women with palpable breast lump of any age attending our hospital during that period and treated with wide local excision or mastectomy and histopathology reported as phyllodes tumor were retrospectively analyzed and included in the study.



A. Recurrent Phyllodes Tumor B. Radical Surgery Performed



C. Reconstruction by Latissimus dorsi flap

All patients underwent radical mastectomy of the affected side. Reconstruction was done by Latissimus dorsi muscle flap.

RESULT

Out of 14 patients, all underwent radical surgery. 9 patients (64%) received post operative radiotherapy after radical surgery. The rest 5 patient (36%) did not turn up for adjuvant radiotherapy. After a follow up period of 1- 2 yrs. only 1 patient (11%) among the post radiotherapy group develops local recurrence. In the non irradiated group 3 patients (60%) develop local recurrence.

Table 1: Pattern Of Recurrence With/without Adjuvant Radiotherapy

CASE	Management Protocol	No. of patients (%)	No. of Recurrence	Percentage of Recurrence
Recurrent Phyllodes tumors of breast, managed with radical breast surgery.	Adjuvant radiotherapy given	9 (64%)	1	11%
	Adjuvant radiotherapy not given	5 (36%)	3	60%
	Total	14	4	29%

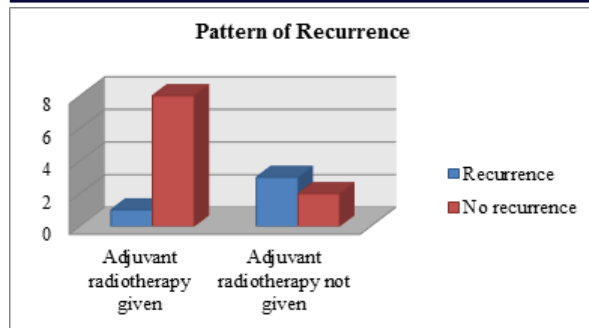


Figure 1: Bar Diagram Showing Pattern Of Recurrence With/without Adjuvant Radiotherapy

DISCUSSION

PT are uncommon tumors of the breast, accounting for only 0.5–2.5% of all breast lumps^[12]. Local recurrence rates of up to 19% have been reported^[12,13]. Local recurrence is often frustrating for both patient and surgeon as further surgery is needed. There is also a risk of the recurrent tumor being malignant even when the initial tumor was benign. More work is needed to better understand the clinicopathological features that predict for local recurrence.

Adjuvant RT appears to be effective in decreasing recurrences after radical breast surgery for borderline or malignant phyllodes tumors, particularly when it is not possible to obtain a wide margin of >1 cm of resection. For some tumors a 1 cm margin may not be possible even with a total mastectomy due to their size or location. Available data indicate that RT will substantially reduce recurrence for these patients. Adjuvant radiotherapy lowered the rates of local recurrence in malignant and borderline tumors^[14]. Radiotherapy was used in our study. It was employed in 9 patients with recurrence tumors, none of them experienced local relapse. The local recurrence rate was 29% comparable with the recurrence rates reported in the literature (8–19%). In some reports, it reached to 36%^[14].

CONCLUSION

Although surgery is the mainstay of management, radiotherapy following radical surgery appears to decrease the local recurrence rates.

CONFLICT OF INTEREST

None

CONSENT

Written informed consent was obtained from the patient for publication of this case report and accompanying images.

REFERENCES

- Rakha EA, Ellis IO. Phyllodes tumor of the breast. In: Textbook of uncommon cancer. Hoboken, NJ: John Wiley & Sons, Inc.; 2012. pp. 243–56.
- Geister DP, Boyle MJ, Malnar KF, McGee JM, Nolen MC, Fortner SM, et al. Phyllodes tumors of the breast: a review of 32 cases. *Am Surg* 2000;66:360–6.
- Calhoun KE, Lawton TJ, Kim JN, Lehman CD, Anderson BO. Phyllodes tumors. In: Harris J, Lippman ME, Osborne CK, Morrow M, editors. *Diseases of the breast*. Philadelphia: Lippincott Williams & Wilkins; 2010. p. 781–92.
- Komenaka IK, El-Tamer M, Pile-Spellman E, Hibshoosh H. Core needle biopsy as a diagnostic tool to differentiate phyllodes tumor from fibroadenoma. *Arch Surg* 2003; 138: 987–90.
- Vetto J, Pommier R, Schmidt W, Wachtel M, DuBois P, Jones M, et al. Use of the “triple test” for palpable breast lesions yields high diagnostic accuracy and cost savings. *Am JSurg* 1995; 169: 519–22.
- Hajdu SI, Espinosa MH, Robbins GF. Recurrent cystosarcoma phyllodes: a clinicopathologic study of 32 cases. *Cancer* 1976; 38: 1502–06.
- Pietruszka M, Barnes L. Cystosarcoma phyllodes. *Cancer* 1978; 41: 1974–83.
- Treves N, Sunderland D. Cystosarcoma phyllodes of the breast: a malignant and a benign tumor. *Cancer* 1951; 4: 1286–332.
- Barth RJ Jr. Histologic features predict local recurrence after breast conserving therapy of phyllodes tumors. *Breast Cancer Res. Treat.* 1999; 57: 291–5.
- Chaney AW, Pollack A, McNeese MD, Zagars GK, Pisters PW, Pollock RE, et al. Primary treatment of cystosarcoma phyllodes of the breast. *Cancer* 2000;89:1502–11.
- Barth RJ Jr, Wells WA, Mitchell SE, Cole BF. A prospective, multi-institutional study of adjuvant radiotherapy after resection of malignant phyllodes tumors. *Am Surg Oncol* 2009;16:2288–94.
- Chua CL, Thomas A, Ng BK. Cystosarcoma phyllodes: Asian variations. *Aust. N. Z. J. Surg.* 1988; 58: 301–305.
- Lindquist KD, van Heerden JA, Weiland LH et al. Recurrent and metastatic cystosarcoma phyllodes. *Am. J. Surg.* 1982; 144: 341–3.
- Pezner RD, Schultheiss TE, Paz IB. Malignant phyllodes tumor of the breast: local control rates with surgery alone. *Int J Radiat Oncol Biol Phys* 2008;71:710–3.