



VENTILATORY SUPPORT WITH THE USE OF NIV, NON-REBREATHABLE MASK AND PRONE VENTILATION IN A COVID PATIENT

General Medicine

Dr. K. Arun Vishnu* Postgraduate, Dept Of Respiratory Medicine, Jawaharlal Nehru Main Hospital And Research Institute.*Corresponding Author

Dr. Athul.C. Angaj Postgraduate, Dept Of Respiratory Medicine, Jawaharlal Nehru Main Hospital And Research Institute.

Dr. Trinath Dash Guide, Sr. Deputy Director , Dept Of Respiratory Medicine,jawaharlal Nehru Main Hospital And Research Institute.

ABSTRACT

Ventilatory Support Has Been Gaining Importance And Momentum In The Past Due To Respiratory Illness Like Copd, Asthma And Also In The Present In View Of The Current On Going Pandemic Where Maintaining The Respiratory Function With Optimum Oxygenation In A Patient Has Been A Lot Challenge Due To Various Risk Factors. We Hereby Are Going To Discuss About A Case Of Covid 19 And Later Developed Post-covid Fibrosis. He Was Managed With Various Modes Of Ventilatory Supports Of A Prolonged Icu Stay With Out Invasive Ventilation, And Later Discharged.

KEYWORDS

CASE REPORT:

A 52 Years Old Known Hypertensive And Diabetic Patient On Regular Medication Presented With Chief Complaints Of Fever Since 4 Days Cough With Mucoid Expectoration Since 4 Days Sob Grade-ii Mmrc No H/o Chestpain, Hemoptysis, Loss Of Consciousness.

On Evaluation- Patient Is Conscious, Coherent And Well Oriented.

Bp-130/80mmhg, Heart Rate-72/min,

Respiratory Rate-26/min, Spo2%-90% At Room Air

Temperature-102^of,

Auscultation – Bilateral Diffuse Fine Inspiratory Crepts Present.

Patient Was Diagnosed To Be Covid-19 Positive By Rat On Day-2 Of Hospital Stay.

- Patient Was Provided Initially With A High Flow Oxygen Through Venturi Mask
- He Was Treated With I.v Broad Spectrum Antibiotics (carbapenems, Macrolides),
- Antiviral Drugs (remdesivir Standard Dose 200mg I.v Od Day-1 Followed By 100mg I.v Od Day 2-5),
- High Dose Iv Steroids (methylprednisolone 125mg Bid) After Inflammatory Markers Report.
- Anticoagulation (low Molecular Weight Heparin 60mg, S/c, bid).
- Antifibrotic (pirfenidone 801mg Tds)
- Supportive Medication In The Form Of Zinc, Vitamin-c, B-complex Etc.
- Even After The Treatment, Patient Had Severe Hypoxemia And Had To Be Put On Niv Support
- Later Was Found To Be Tolerating Niv Well And Then Was Provided Non-rebreathable Mask Support
- Patient Had A Relatively Long Hospital Stay (during The Course Of Which He Developed Secondary Infections, That Were Adequately Managed), With Niv And Nrm Support
- Later The Patient Was Put On Prone Ventilation- 4-5 Cycles/day With Each Cycle Lasting For 2-3 Hours
- Finally He Was Discharged With Spo2 Of 92% With Domiciliary O2 Support On Demand.

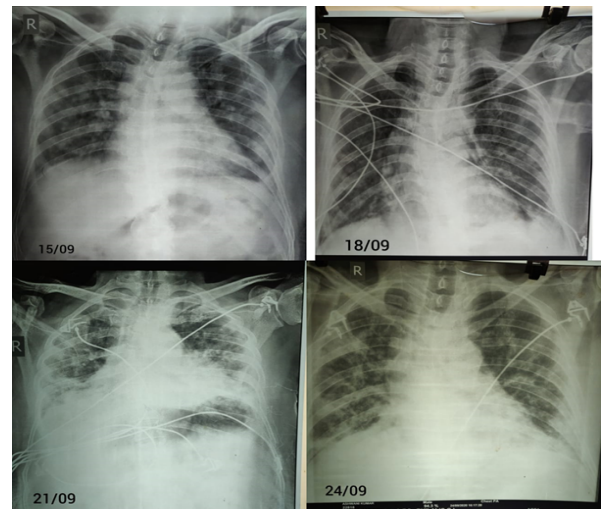
His Routine Blood Investigations Revealed

Investigation	05/09/20	15/09/20	16/9/20	23/09/20	1/10/20	11/10/20	21/10/20
WBC (cumm)	11,600	13,400	15,900	14,600	17,100	11,800	12,000
Hb (gm/dl)	14.1 g m/dl	13.8	13.5	12.9	13.2	13.4	13.6

Platelet count (cumm)	1,35,000	1,28,000	1,22,000	1,20,000	1,000	1,14,000	1,25,000
Sr.CREATINE (mg/dl)	0.7	0.8	0.9	1.0	1.3	0.8	0.9
Bilirubin (mg/dL)	1.5 (D-1.2 & I-0.3)	1.9 (D-1.1, I-1.8)	1.4 (D-0.7 & I-0.7)	1.3 (D-0.8 & I-0.5)	1.2 (D-0.6) & I-0.6)	1.2 (D-0.7, I-0.5)	1.1 (D-0.6 & I-0.5)
LDH (U/L)	890	1020		1532	1328	765	565
Na+(mmol/l)	127			132		134	
K+(mmol/l)	3.4			3.5		3.9	
Albumin (g/dL)	3.2	3.1				4	
CRP (mg/Dl)	1.2			2.4		1.2	0.6
SGOT (U/L)	25	86		98		87	68
SGPT (U/L)	62	201		220		190	160
CA+2			8.1			6	
D-DIMER (mcg/ml) FEU		2		1.6		1.4	0.6
Sr.Ferritin (ng/ml)		1500		1650		1543	700
IL-6 (pg/ml)		10		45	70	36	12

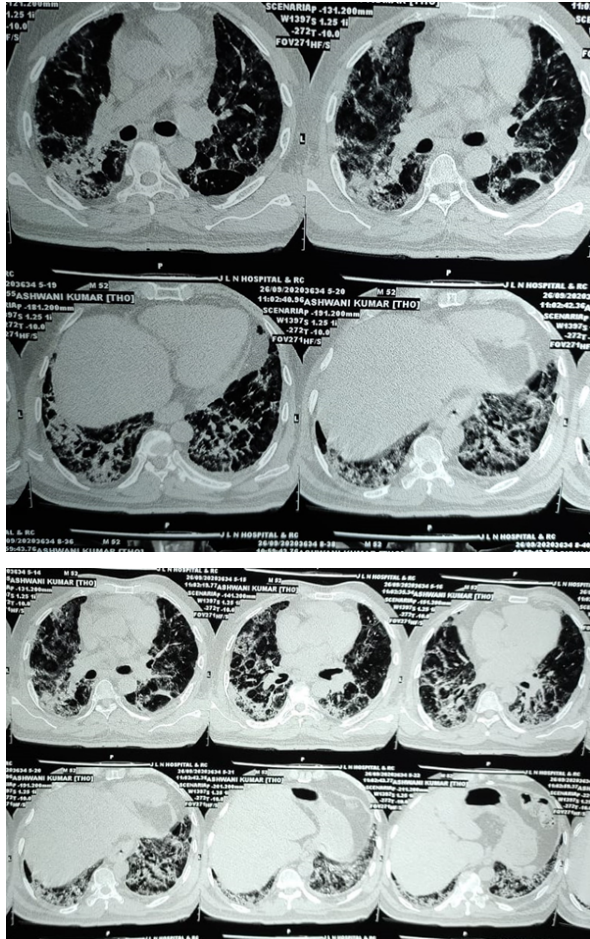
Patients Radiological Profile:

Chest X-ray: B/I Fluffy Homogenous Shadows All Over The Lung Fields



HRCT CHEST:

**S/o Bilateral Diffuse Ggo, Sub Pleural Fibrotic Bands With Thickened Inter Lobular Septa.
Corads - 6 (confirmed Case Of Covid -19)
Ct Severity Index - 21/25**



Patient Was Initially Managed By Hospital Covid Protocol. He Was Responding Well To Treatment Initially. He Was Found To Be Desaturating From Day 6 Of His Hospital Stay And Was Shifted To Icu For Critical Care Support. Stayed In Icu For A Period Of 10 Days With Niv Support With Escalated Antibiotics And Other Supportive Measures.

Shifted To Ward And Put On Oral Anticoagulants, Started Antifibrotics (pirfenidone 801mg Tds) And Put On Non-rebreathable Mask. He Was Maintaining Saturation With Nrm, So He Was Started On Intermittent Prone Ventilation Consisting Of 4-5 Cycles/day With Each Cycle Lasting Upto 2-3 Hours. He Was Also Advised To Do Incentive Spirometer.

Patient Improved Symptomatically And Maintaing Saturation And Was Hence Discharged With Domiciliary O2 Support On Demand.

DISCUSSION:

Ventilatory Support And Infection Control Seems To Be Main Pillars Of Covid-19 Management. However Its Challenging To Decide Or Make A Standard Treatment Protocol Since Every Treatment Plan Needs To Be Individualised Accordingly Taking Into The Considerations Of The Patient's Response To Treatment And His Pulmonary Function.

Here In Our Patient, Initially He Was Found To Be Responding Well To Treatment And Later Was Found Deterioating. Preventing And Controlling The Secondary Infection Also Seems To Play An Important Role In Patient Response To Treatment And His Prognosis.

Coming To Ventilatory Support, Deciding Ventilation Strategy Is Challenging Because Of The Hetrogenous Lung Pathology. Also An Early And Timely Intervention With Non-invasive Ventilation Has Shown That The Need For Intubation Can Be Reduced.^[10]

In Our Case, Niv Support Was Well Tolerated. In Shifting To Non-rebreathable Mask Ventilation Too, His Response Was Well-noticed. This Gave Us Time And Thought To Give A Trial Of Awake And Prone Ventilation As Recently Suggested For Management Of Covid-19 Patients.^[8] Also Studies Suggest That Niv Is Successful Only In 75-90% Of All Cases, Which Depends On Many Factors, Such As Severity Of Acute Respiratory Failure, Training And Experience Of Medical Personnel, And The Place Of Respiratory Support.^[11]

Providing Mechanical Ventilation With Intubation Can Never Be Replaced By Non-invasive Ventilation. But Non-invasive Ventilation, nrm, prone And Awake Ventilation Can Be Used Early To Reduce Deterioration To An Extent That Invasive Ventilation Can Be Avoided.^[12]

Coming To Prone Ventilation, although A Little Cumbersome To Patient It Proves As An Effective, Low Cost Method To Implement As A Ventilatory Support To Provide A Beneficial Outcome In A Limited Resource Setting.

CONCLUSION:

- Steroids, Anti-inflammatory, Anti-virals And Ventilatory Support Seems To Be The Mainstay Of Treatment In Covid-19 Patients
- Patients Who Are Developing Early Fibrosis Should Be Started On Anti-fibrotics Early
- Patients Who Are Going Into Early Respiratory Failure Should Be Meticulously Managed With Non-invasive Ventiation
- Patients With High Ct Severity Index Can Also Be Managed With Non-invasive Ventilation Without Requiring The Need For Intubation If Timely And Meticulously Intervened. However This School Of Thought Cannot Be Generalised To A Larger Population Studies As This Was Effective In Our Case.
- Further Studies Giving Importance To Non-invasive Ventilation, awake And Prone Ventilation Can Help In Providing A Better Ventilatory Support Strategy To Such Type Of Severly Sick Patients So As To Help Us In Tackling Future Hurdles In The Mangement Of Covid Patients.

REFERENCES

1. Nasibova EM, Pashayev CN (2020) The Use of Non-Invasive Ventilation (NIV) in the Treatment of Patients with COVID-19. *J Intensive & Crit Care* Vol.6 No.2:5
2. COVID-19: Respiratory support outside the intensive care unit McEnery, Tom et al. *The Lancet Respiratory Medicine*, Volume 8, Issue 6, 538 – 539
3. Use of non-invasive ventilation for patients with COVID-19: a cause for concern? Arulkumar, Nishkantha et al. *The Lancet Respiratory Medicine*, Volume 8, Issue 6, e45
4. Respiratory support for patients with COVID-19 infection. Namendys-Silva, Silvio A. *The Lancet Respiratory Medicine*, Volume 8, Issue 4, e18
5. Chawla R, Nasa P. Ventilatory Management of COVID-19-related ARDS: Stick to Basics and Infection Control. *Indian J Crit Care Med* 2020;24(8):609–610
6. Möhlenkamp, S., Thiele, H. Ventilation of COVID-19 patients in intensive care units. *Herz* 45, 329–331 (2020)
7. Privitera, D., Angaroni, L., Capsoni, N. et al. Flowchart for non-invasive ventilation support in COVID-19 patients from a northern Italy Emergency Department. *Intern Emerg Med* 15, 767–771 (2020)
8. Mahendra Damarla, Sandra Zaeh. et al. Prone Positioning of Nonintubated Patients with COVID-19." *American Journal of Respiratory and Critical Care Medicine*, 202(4), pp. 604–606
9. Franco C, Facciolo N, Tonelli R, et al. Feasibility and clinical impact of out-of-ICU non-invasive respiratory support in patients with COVID-19 related pneumonia. *Eur Respir J* 2020; in press (<https://doi.org/10.1183/13993003.02130-2020>)
10. Brusasco C, Corradi F, Di Domenico A, et al. Continuous positive airway pressure in Covid-19 patients with moderate-to-severe respiratory failure. *Eur Respir J* 2020; in press (<https://doi.org/10.1183/13993003.02524-2020>)
11. Oranger M, Gonzalez-Bermejo Jesús, Dacosta-Noble P, et al. Continuous positive airway pressure to avoid intubation in SARS-CoV-2 pneumonia: a two period retrospective case-control study. *Eur Respir J* 2020; in press (<https://doi.org/10.1183/13993003.01692-2020>)
12. Chris Carter, Helen Aedy, Joy Nottter. COVID-19 disease: Non-Invasive Ventilation and high frequency nasal oxygenation, *Clinics in Integrated Care*, Volume 1, 2020, 100006, ISSN 2666-8696, (<https://doi.org/10.1016/j.intcar.2020.100006>)