



CHEST X-RAY FINDINGS IN COVID-19 PNEUMONIA: A PICTORIAL REVIEW

Radiology

Dr. Zohra Ahmad*	MD, FRCR, Assistant Professor, Department of Radiology, Gauhati Medical College and Hospital, Guwahati, Assam. *Corresponding Author
Dr. Parul Dutta	MD, DMRD, Professor and Head of the Department, Department of Radiology, Gauhati Medical College and Hospital, Guwahati, Assam.
Dr. Deepjyoti Das Choudhury	Postgraduate Trainee, Department of Radiology, Gauhati Medical College and Hospital, Guwahati, Assam.
Dr. Satabdi Kalita	Postgraduate Trainee, Department of Radiology, Gauhati Medical College and Hospital, Guwahati, Assam.
Dr. Zohaib Hussain	Senior Resident, Department of Radiology, Gauhati Medical College and Hospital, Guwahati, Assam.
Dr. Zainab Ahmad	MD, Associate Professor, Department of Anaesthesiology, AIIMS Bhopal.

ABSTRACT

Corona Virus Disease 19 or COVID-19, was first detected in Wuhan province in China in December 2019 and reported to the World Health Organization (WHO) on December 31, 2019 [1]. It was declared a pandemic on March 11th, 2020 [2] and has till now affected 40 million people all around the world resulting in 1.1 million deaths (as of 18th Oct, 2020) [3]. As the world is reeling under the burden of the disease, it has been imperative for the radiologists to be familiar with the imaging appearance of the disease. Thoracic imaging with chest X-ray and CT is the key modality for the diagnosis and management of respiratory diseases. Although CT is more sensitive, the immense challenge of disinfection control in the modality may disrupt the service availability and portable X-ray may be considered to minimize the risk [4]. Use of portable X-ray has played a vital role in all the areas around the world during this pandemic.

The purpose of this pictorial review is to represent the frequently encountered features and abnormalities in chest X-ray and strengthen the knowledge of the health-care workers in this war against the pandemic.

KEYWORDS

COVID-19, ground glass opacities, consolidation, viral pneumonia

INTRODUCTION

Within only 3 months of identification of COVID-19 in Wuhan, China, it became a pandemic around the world. Covid 19 is caused by severe acute respiratory syndrome coronavirus 2 (SARS-CoV-2). The spread primarily occurs during close contact between people, via small droplets produced by coughing, sneezing and talking [5]. It is most contagious during the first three days after the onset of symptoms, although spread is possible before symptoms appear, and from people who do not show symptoms [5, 6]. Most of the cases are asymptomatic with few showing symptoms ranging from fever, cough, fatigue, myalgia, shortness of breath, and loss of sense of smell to severe respiratory distress warranting ventilator support [5, 7, 8]. Current gold standard test for coronavirus is reverse-transcription polymerase chain reaction (RT-PCR) on nasopharyngeal and throat swabs however it is limited by low sensitivity (63 % for nasal swabs and 32% for pharyngeal swabs) [9,10,11].

Chest imaging has been considered as part of the diagnostic workup of patients with suspected or probable COVID-19 disease where RT-PCR is not available, or results are delayed or are initially negative in the presence of symptoms suggestive of COVID-19. Imaging has been also considered to complement clinical evaluation and laboratory parameters in the management of patients already diagnosed with COVID-19 [12].

The main focus of chest imaging is on CT. As per a study in China in February, 2020 the sensitivity of chest CT was higher in comparison to initial nasopharyngeal swabs [13, 14]. Chest X-ray (CXR) is a less sensitive modality in the detection of COVID-19 lung disease compared to CT, with a reported baseline CXR sensitivity of 69% [15]. However portable chest radiography has the advantage of eliminating the need of patient transfer and also reduce manpower and consumables use. It is also useful in follow up to identify temporal evolution of findings. If CXR is positive for pneumonia in a suspected COVID-19 patient, CT can be avoided.

Chest radiographs may be normal in early or mild disease. Findings are most extensive about 10-12 days after onset of symptoms [3]. The most frequent findings are airspace opacities, whether described as

consolidation or less commonly, ground glass opacity [16, 17]. The distribution is most often bilateral, peripheral, and lower zone predominant [16, 17, 18], however in early cases unilateral GGO or consolidation may also be observed. In contrast to parenchymal abnormalities, pleural effusion is rare (3%) [16].

We describe a spectrum of common portable CXR findings in COVID-19 positive patients, admitted to a tertiary level hospital in this article.

1. Ground Glass Opacities

Initial CXRs are often normal with few showing peripheral haziness that is difficult to appreciate [15]. This haziness is not dense enough to obscure the underlying pulmonary vessels and bronchi and also termed as ground glass opacities. With such findings, patients are often asymptomatic with few showing symptoms like cold, sore throat and myalgia [15]. Ground glass opacities are often multifocal and peripheral [Fig 2a-h] and may show associated atelectatic bands [Fig 1f, 3b] or interstitial opacities [figure 2c, 2h]. During initial infection, GGO may also be unifocal and unilateral [Fig 1a-f].

2. Consolidation

With the progress of the disease, dense opacities obscuring vessels and bronchial walls may be seen along with ground glass opacities. These consolidations are generally noted bilaterally with basal predominance like other viral pneumonias [Fig 3]. This is in contrast to bacterial pneumonias that are generally unilateral and involve a single lobe. Unilateral consolidation can also be seen in COVID-19 pneumonia, however it is more commonly peripheral predominant. Perihilar consolidation is an uncommon finding [16] [Figure 3a]. Covid 19 pneumonia can lead to rapidly progressive ARDS where CXR manifestations may progress from ill-defined unifocal patchy ground glass opacity to multifocal consolidation/GGO [4a-b] and finally bilateral panlobar confluent consolidations [Fig 4c]. [20]

3. Atypical Findings

Lung nodules, hilar lymphadenopathy [Fig 5a] and cavitation [Fig 5b] are rare in the setting of COVID 19 [19]. Pleural effusions are also exceedingly rare. However few cases are reported in advanced stages [Fig 2a, 3e]. Chest wall subcutaneous emphysema and

pneumomediastinum have also been reported which may be spontaneous or barotrauma related.^[21]

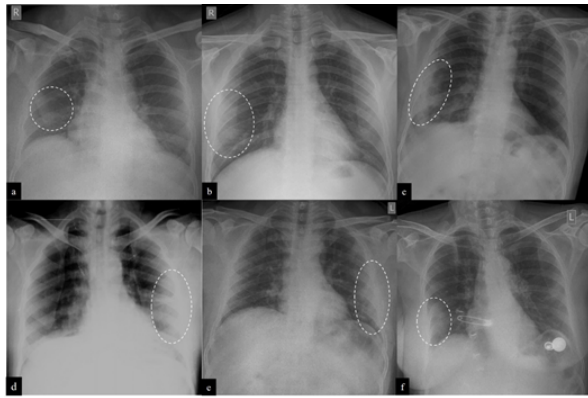


Fig 1: Unilateral GGO. a: Right lower zone paracardiac ground glass opacity (dotted circle). b: Right lower zone peripheral GGO (dotted circle). c: Right mid and lower zone GGO (dotted circle). d: Left mid and lower zone peripheral GGO (dotted circle). e: Left mid and lower zone peripheral GGO (dotted circle). f: Right lower lobe peripheral ground glass opacity (dotted circle). Atelectatic bands seen in left midzone.

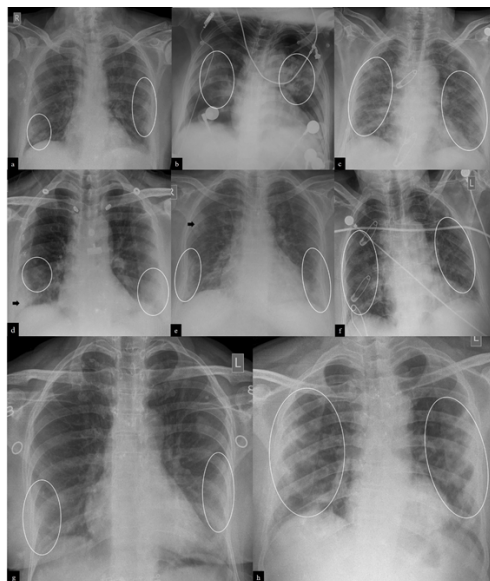


Fig 2: Bilateral(B/L) GGO. a: Patchy GGO (circle) in right lower & left mid/lower zones with left sided minimal pleural effusion. b: Ill-defined GGO in B/L mid zones in perihilar location (circle). c: B/L patchy GGO and interstitial opacities. d: B/L lower zone peripheral GGO (circle) with right lower zone consolidation (arrow). e: Right upper (arrow) and B/L lower zone peripheral GGO and reticulation (circle). f: Patchy GGO in B/L mid and lower zones (circle). g: B/L lower zone peripheral GGO (circle). h: Patchy GGO & interstitial opacities in B/L mid/lower zones (circle) peripherally.

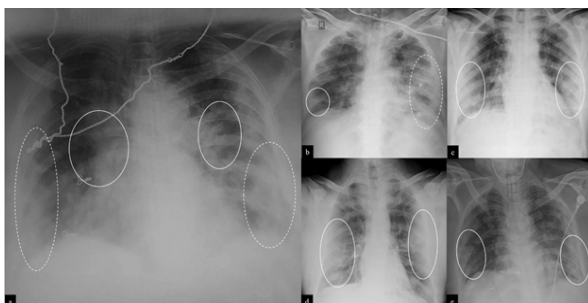


Fig 3: B/L Patchy consolidations. a: GGO and patchy consolidation in B/L perihilar regions (solid circle) and peripheral location (dotted circle) with mid/lower zone predominance. b: Right lower zone

peripheral GGO (solid circle) with left mid/lower zone consolidation (dotted circle). Atelectatic band seen in right lower zone. c: B/L mid / lower zone patchy peripheral consolidations (solid circle). d: B/L mid/lower zone peripheral, patchy consolidations and GGO (solid circle). e: B/L mid/lower zone patchy consolidation and GGO (solid circle) with peripheral and basal predominance & left sided pleural effusion

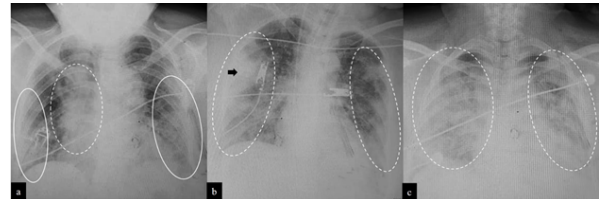


Fig 4: ARDS type manifestations. a: Right mid and lower zone perihilar and paracardiac consolidation (dotted circle) and left mid and bilateral lower zone peripheral GGO (solid circle). b: Right mid zone peripheral consolidation (arrow) and bilateral GGO (dotted circle), predominantly peripheral in location. c: Confluent consolidation in all zones of right lung and mid and lower zones of left lung along with GGO (dotted circle).

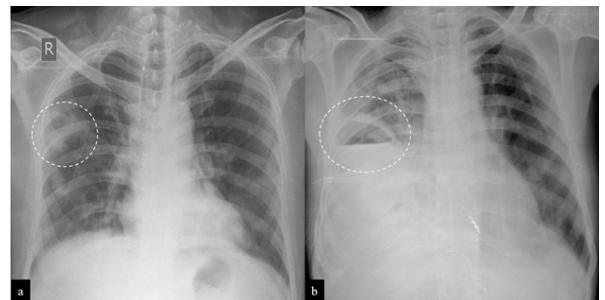


Fig 5: Atypical findings. a: Ill-defined GGO with central lucency (white dotted circle) with left hilar lymphadenopathy. b: Cavitary lesion in right midzone with air fluid level

CONCLUSION

Although CT is more sensitive than CXR for COVID pneumonia, typical findings of COVID 19 can be identified on CXR. Ground glass opacities and consolidations are the commonest findings with typical pattern of peripheral and basal predominance. Like other viral pneumonias, COVID 19 is also generally bilateral and multifocal as opposed to bacterial pneumonia. Due to better availability and infection control measures while using portable CXR, it can be used to monitor the disease progression while eliminating the need of patient transfer. The medical fraternity is now relying more and more on chest radiography for monitoring of the patients worldwide.

REFERENCES

1. World Health Organization website. Pneumonia of unknown cause, China. February 13, 2020.
2. WHO Director-General's opening remarks at the media briefing on COVID-19. March 2020.
3. COVID-19 Dashboard by the Center for Systems Science and Engineering (CSSE) at Johns Hopkins University (JHU). Johns Hopkins University. 18th October, 2020.
4. ACR Recommendations for the Use of Chest Radiography and Computed Tomography (CT) for Suspected COVID-19 Infection. American College of Radiology. 11 Mar, 2020.
5. Q&A on coronaviruses (COVID-19). World Health Organization. 17 April 2020.
6. How COVID-19 Spreads. Centers for Disease Control and Prevention (CDC). 2 April, 2020.
7. Hopkins C. "Loss of sense of smell as marker of COVID-19 infection". Ear, Nose and Throat surgery body of United Kingdom. 28 March, 2020.
8. Coronavirus Disease 2019 (COVID-19)—Symptoms. U.S. Centers for Disease Control and Prevention (CDC). 20 March, 2020.
9. Wang W, Xu Y, Gao R, Lu R, Han K, Wu G, Tan W. Detection of SARS-CoV-2 in Different Types of Clinical Specimens. *Jama*. March 2020; 323(18): 1843-1844.
10. Bhadra S, Jiang Y.S., Kumar M.R., Johnson R.F., Hensley L.E., Ellington A.D. Real-time sequence-validated loop-mediated isothermal amplification assays for detection of Middle East respiratory syndrome coronavirus (MERS-CoV) *PLoS One*. 2015; 10
11. Chan J.F., Choi G.K., Tsang A.K., Tee K.M., Lam H.Y., Yip C.C. Development and evaluation of novel real-time reverse transcription-PCR Assays with locked nucleic acid probes targeting leader sequences of human-pathogenic Coronaviruses. *J Clin Microbiol*. 2015; 53:2722-2726.
12. Use of chest imaging in COVID-19, A RAPID ADVICE GUIDE. WHO. 11 June, 2020.
13. Ai T, Yang Z, Hou H et al. Correlation of Chest CT and RT-PCR Testing in Coronavirus Disease 2019 (COVID-19) in China: A Report of 1014 Cases. *Radiology*. 2020; 200642.
14. Fang Y, Zhang H, Xie J et al. Sensitivity of Chest CT for COVID-19: Comparison to RT-PCR. *Radiology*. 2020; 200432.
15. Wong HYF, Lam HYS, Fong AH, et al. Frequency and distribution of chest radiographic findings in COVID-19 positive patients. *Radiology* 2019; 201160.
16. Rodrigues, J.C.L. et al. An update on COVID-19 for the radiologist - A British society of

- Thoracic Imaging statement. *Clinical Radiology*. 2020.
17. Another Decade, Another Coronavirus. (2020) *New England Journal of Medicine*. 2020.
 18. Jeffrey P Kanne, Brent P Little, Jonathan H Chung, Brett M Elicker, Loren H Ketai. Essentials for Radiologists on COVID-19: An Update—Radiology Scientific Expert Panel. 2020.
 19. Salehi S, Abedi A, Balakrishnan S, Gholamrezanezhad A. Coronavirus disease2019 (COVID-19): a systematic review of imaging findings in 919 patients. *AJRAM J Roentgenol* 2020;14(March):1-7.
 20. Lorente E. Eurorad Case 16660. "Rapidly progressive ARDS secondary to COVID-19 infection". 2020.
 21. Chen N, Zhou M, Dong X, Qu J, Gong F, Han Y, et al. Epidemiological and clinical characteristics of 99 cases of 2019 novel coronavirus pneumonia in Wuhan, China: a descriptive study. *The Lancet*. 2020 Feb 15;395(10223):507–13.