



CLINICAL STUDY OF BENIGN LESIONS OF LARYNX IN TERTIARY CARE HOSPITAL

Dr. Naga Sowmya Dasari

Postgraduate Department of E.N.T Alluri Sitarama Raju Academy of Medical Sciences
Eluru 534005, West Godavari district Andhra Pradesh ,India

Dr. Deeganta Mohanty

Professor, Department of E.N.T, Alluri Sitarama Raju Academy of Medical Sciences
Eluru 534005, West Godavari district Andhra Pradesh ,India

Dr. Polletikurti Vithal Prasad*

Associate Professor, Department of E.N.T, Alluri Sitarama Raju Academy of Medical Sciences Eluru 534005, West Godavari district Andhra Pradesh ,India. *Corresponding Author

ABSTRACT

Aim Of Study: To analyse over a period of 1 Year 6 Months , demographics such as age, sex, distribution, occupation, the site of involvement, symptomatology and prognosis of the most frequent benign lesions of larynx.

Materials And Methods: 50 patients presenting with hoarseness of voice and diagnosed with benign lesion of larynx in ENT OPD of Alluri Sitarama Raju Academy Of Medical Sciences, Eluru, were included in the study after taking their consent and the study was carried out for a period of 1 Year 6 Months from August 2018 to February 2020.

Results: In this study, it was noted that males were predominantly involved, maximum incidence between 31-40 years. Vocal cord nodule was the most common benign lesion of larynx. Most important predisposing factor was being vocal abuse in all the cases. Treatment given included speech therapy, medical management and MLS according to the diagnosis and patients were followed up for six months. All patients with Reinke's edema were normal at follow up.

Conclusion: It was observed that vocal abuse was the most common predisposing factor for benign lesions of larynx and a multimodality treatment is necessary including medical, surgical and speech therapy to prevent recurrence.

KEYWORDS

benign lesions, hoarseness, vocal abuse, vocal nodule.

INTRODUCTION:

'Voice' is the acoustic outputs from the vocal tract that are characterized by their dependence on vocal fold vibratory inputs¹. Voice disorder can have a significant influence on vocational, social and the emotional adjustment of patients². Benign neoplasms of the larynx constitute an interesting array of lesions and have been defined as —An abnormal mass of tissue in the larynx, the growth of which exceeds and is uncoordinated with that of normal tissue and persists in the same excessive manner after cessation of stimuli which evoked the change³. Benign lesions of the larynx generally produce a common symptomatology known as dysphonia⁴. These lesions may affect voice quality and excessive growth may cause respiratory distress. Vocal nodules, polyps or a cyst does not rule out malignancy, unless the lesion is resolved with treatment or it is pathologically benign⁵.

AIMS & OBJECTIVES OF THE STUDY:

1. To analyse the demographics such as age, sex, distribution, occupation, the site of involvement, symptomatology of the most frequent benign lesions of larynx.
2. To analyse the prognosis of the most frequent benign lesions of larynx.

MATERIALS AND METHODS:

The present study Clinical study of Benign Lesions of Larynx has been carried out in the Department of ENT, Alluri Sitarama Raju Academy Of Medical Sciences, Eluru over a period of 1 Year 6 Months from August 2018 to February 2020. During this period patients who presented with hoarseness of voice were evaluated and 50 patients with benign lesions of larynx were included in the present study after taking their consent.

Inclusion Criteria:

1. All patients attending ENT OPD with hoarseness of voice, throat pain, foreign body sensation in the throat, vocal fatigue, difficulty in breathing, difficulty in swallowing.
2. Age 5-65 years.
3. Both males and females.

Exclusion Criteria:

1. Age below 5 years and above 65 years.
2. Patients with clinical diagnosis of malignancy of larynx.

3. Patients with speech defect due to central nervous system lesions.
4. Patients with oral and pharyngeal pathology leading to change in voice.
5. Patients with nasal and nasopharyngeal pathology leading to change in voice.

METHODOLOGY:

A detailed history was taken, a complete general physical examination and a thorough ENT examination was done to arrive at the final diagnosis. The protocol followed in our institute is as follows. Vocal cord nodule and vocal cord polyp patients were advised micro-laryngeal surgery to excise the lesion followed by voice rest. Those who refused were put on medical line of management including antibiotics, antacids, steam inhalation, steroids and speech therapy. Reinke's edema patients were given medical line of management and voice rest. Patients were followed up for 6 months to assess the persistence or regression of the lesion. Those patients with persistence of the lesion were advised surgical excision.

RESULTS:

Table-1: Age and Sex Distribution.

Age in Years	Males		Females		Total	
	No	%	No	%	No	%
<10 yrs	0	0	0	0	0	0
11-20	0	0	0	0	0	0
21-30	8	29.62	9	39.13	17	34
31-40	3	48.14	10	43.47	23	46
41-50	3	11.11	3	3.04	6	12
51-60	2	7.4	1	14.34	3	6
61-70	1	3.7	0	0	1	2
>70yrs	0	0	0	0	0	0

In our study the most common age group involved was between 31-40 years.

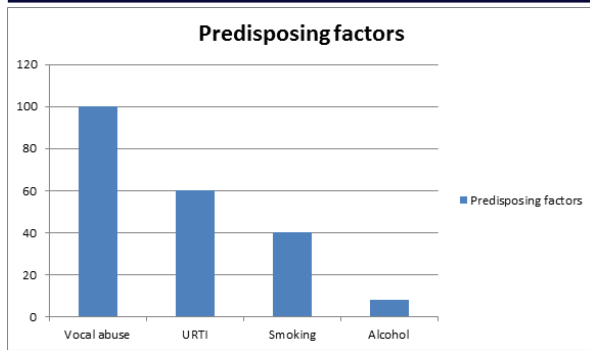


Figure:1: Predisposing Factors.

Vocal abuse was the main predisposing factor noticed in 100% of patients, others being smoking, upper respiratory tract infection and alcohol consumption. (Figure:1)

Table: 2: Occupation.

Occupation	Males		Females		Total	
	No	%	No	%	No	%
Business	15	55.55	2	8.69	17	34
Housewife	0	0	6	26.08	6	12
Teacher&Professional voice users	8	29.62	13	48.14	21	42
Students	2	7.4	2	8.69	4	8
Others	2	7.4	0	0	2	4

In our study we saw that Teacher & professional voice users (48.14%) among females and business man (55.55%) among males were most commonly affected by these lesions. (Table: 2)

Based on duration of hoarseness maximum number of patients i.e., 16 cases (32%) presented during 3 – 6 months.

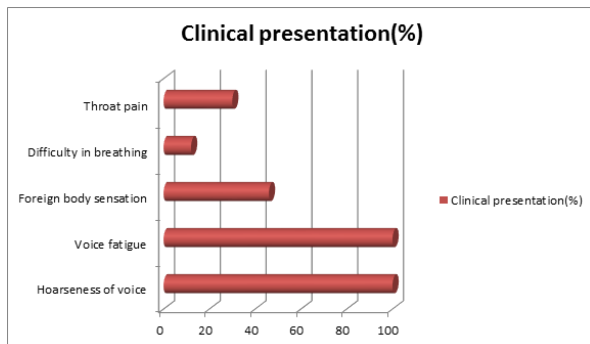


Figure:2: Clinical Presentation.

In our study the commonest clinical presentation noticed was hoarseness of voice and vocal fatigue (100%), few patients also presented with foreign body sensation in throat and difficulty in breathing and throat pain (Figure: 2)

Table:3: Diagnosis.

Findings	No of cases(n=50)	Percentage (%)
Vocal cord nodule	21	42
B/LVocal cord polyp	3	6
Right Vocal cord polyp	8	16
Left Vocal cord polyp	6	12
Reinke'sEdema	12	24

In our study Vocal cord nodule was the most common condition (42%).

A combined modality of treatment was given to patients, including speech therapy, speech therapy along with medical line of management. Few patients underwent MLS surgery (Micro laryngeal surgery) and post-op speech therapy.

During follow up at 6 weeks, 12 patients with Vocal cord nodule, 2 patient with B/L Vocal cord polyp, 4 patients with right vocal cord

polyp, 4 patients with left vocal cord polyp ,12 patients diagnosed with Reinke'sedema were free from the lesion during the follow up at six months.

DISCUSSION:

Benign lesions of larynx constitute an interesting array of lesions, etiological factors for lesions such as vocal nodules, vocal polyps, mucosal hemorrhage, intracordal cyst seems to be vibratory trauma⁶. Vocal cord nodules appear as symmetric bilateral massesions, white to opaque, firm and present at the junction of anterior and middle third of vocal folds. Vocal cord polyps are more commonly unilateral, translucent, red pedunculated arise in the free edge of anterior third of vocal fold⁷. Reinke'sedema is also known as polypoidal degeneration, in which a chronic accumulation of gelatinous mucoid material develops in Reinke's space⁸.

A multimodality mode of treatment is necessary to avoid recurrence of these lesions. Primary supportive medical treatment with adequate hydration, mucolytic agents like ambroxyl, carbocystine and brotuxine are believed to break down thick secretions, thereby supplementing therapy. Systemic antihistamine and decongestants, short term corticosteroids for reducing edema and Antibiotics for upper respiratory tract infections⁹.

Two general types of instruction relate specifically to direct voice therapy. The first is recovery and second is training. Recommendation include complete vocal silence for a week or two, no whispering, limited vocal use in which speaking is allowed only when absolutely necessary, reduced vocal intensity, elimination of singing, limitation of physical exercise and activities that cause the breath to be impounded by the closure of glottis and avoiding coughing and clearing of throat whenever possible. If the recovery procedures followed by training that modifies previous habit patterns and replaces them with more efficient phonatory behaviours¹⁰.

In a 2 year prospective study males were seen to predominate over females with a ratio of 4:1. Incidence of vocal polyp was 37.5% followed by vocal nodule 27.5%, multiple laryngeal papillomatosis 10%, hemangioma 10%, epiglottic cyst 5%, vocal cord cyst 7.5% and intubation granuloma 2.5%¹¹.

CONCLUSION:

In our present study, it is seen that benign lesions of larynx were more common in males, maximum incidence between 31-40 years. Business men among males and Teachers and Professional voice users among females were most affected.

Bilateral vocal cord nodule was the most common lesion apart from vocal cord polyp (bilateral and unilateral), Reinke'sedema. Vocal abuse was a strong predisposing factor in all the cases included in the study others being upper respiratory tract infection, smoking and alcohol consumption. Hoarseness of voice and voice fatigue was the most common clinical presentation, foreign body sensation in the throat, difficulty in breathing were the other clinical presentations. Definitive treatment of micro laryngeal surgery and voice rest was advised to patients with vocal cord nodules and vocal cord polyp and the same was executed in those patients were consent for surgery was given. Conservative management including medical management and speech therapy was advised to those patients who refused surgery and patients with Reinke'sedema. All cases at 6 months follow up showed complete resolution of the lesion in patients with Reinke'sedema , 52.94 % of patients with vocal cord nodule, 66.66 % of patients with bilateral vocal cord polyp, 66.66 % of patients with left vocal cord polyp and 50 % of patients with right vocal cord polyp.

REFERENCES:

1. R. R.Bhanu Murthy, DR. P.FazuluRahman Khan, DR.S.Raghavendra Deepak A Clinical Study of Benign Lesions of Larynx and Its Management In a series of 20 cases and review of literature Indian Journal of Applied Research, Vol.6, Issue : 5 MAY 2016
2. Buche, Aniket&Garud, Sachin &Jaiswal, Subhalakshmi&Chamania, Gaurav. (2016). Benign Lesions of Larynx – A Clinicopathological Study.IOSR Journal of Dental and Medical Sciences. 15. 09-17. 10.9790/0853-1509010917
3. D. Sridhar & J. Bhupender&Dham, Ruchima& A. Shobhan& K. Nagaraj& K. Srinivas& C. Kumuda& B. Srikanth. (2016). BENIGN LESIONS OF LARYNX - A CLINICAL STUDY OF 50 CASES. Journal of Evidence Based Medicine and Healthcare. 3. 72-77. 10.18410/jebmh/2016/16.
4. Saudi, S. Benign lesions of the Vocal Cords in different ages: prospective Study of 60 Cases. Journal of Medical Science and Technology,2013;2(3),130-134.
5. Ahmed, S. U., Kabir, M., Alam, A. K., Hasan, D. M., Ahmed, K. U., & Khan, H. S.

- Benign vocal cord lesions-a study of 25 cases. Bangladesh Journal of Otorhinolaryngology, 2006.
6. Muniraju. M, Vidya. H. Clinical study of benign lesions of larynx. Int J Med Res Rev 2017;5(03):229-234doi:10.17511/ijmrr.2017.i03.03.
 7. Johns MM. Update on the etiology, diagnosis, and treatment of vocal fold nodules, polyps, and cysts. Curr Opin Otolaryngol Head Neck Surg. 2003 Dec;11(6):456-61.
 8. Zeitels SM, Hillman RE, Bunting GW, Vaughn T. Reinke's edema: phonatory mechanisms and management strategies. Ann Otol Rhinol Laryngol. 1997 Jul;106 (7 Pt 1):533-43.
 9. Sharad Maheshwari. Management of hoarseness. Asian journal of ear, nose and throat, 2003- March. April. Vol.1:No.1: 1-9.
 10. John Jacob Ballenger, James B. Snow, Jr. Otolaryngology, Head and Neck Surgery. 15th edition. Williams and Wilkins. 1996; 438-465.
 11. Doloi, P. K., Khanna, S. A Study of Management of Benign Lesions of the Larynx. International Journal of Phonosurgery and Laryngology, 2011; 1(2), 61