



DIAGNOSIS OF LIVER PATHOLOGY BY ULTRASOUND AT DMCH, LAHERIASARAI, BIHAR

Pathology

Dr. MeghaJha	M.B.B.S., M.D. (Pathology), Tutor, Department of Pathology, Darbhanga Medical College, Laheriasarai, Bihar.
Dr. Hari Shankar Mishra*	M.B.B.S., M.D. (Pathology), Associate Professor, Department of Pathology, Darbhanga Medical College, Laheriasarai, Bihar. *Corresponding Author
Dr. [Prof.] Ajit Kumar Chaudhary	M.B.B.S., M.D. (Pathology), Professor and Head of Department, Department of Pathology, Darbhanga Medical College, Laheriasarai, Bihar.
Dr. Debarshi Jana	Young Scientist (DST) Institute of Post-Graduate Medical Education and Research, A.J.C. Bose Road, Kolkata-700020, West Bengal, India.

ABSTRACT

Introduction: From many years ultrasonography (USG) is used to evaluate liver diseases. Common liver diseases like hepatomegaly, cirrhosis, fatty degeneration, metastatic deposition, liver abscesses. Ultrasound is non invasive, safe, effective, low-cost, time conserving and primary investigation for liver pathologies. Study objective was to ascertain ultrasound techniques assist in diagnosing different common liver pathological diseases.

Material and Methods: 592 patients were selected from outpatient departments with clinical suspicion of abdominal pathology. Total abdominal scans of all patients were performed by using 3-5MHz frequency convex transducer.

Results: There were 243 patients with positive ultrasound findings revealed that 48% were clinically suspected having liver related common pathologies and 52 were not clinically suspected. Out of those remaining 349 were negative ultrasound 31 (11%) cases were clinically suspected.

Conclusion: Ultrasonography allows for reliable and accurate detection of moderate-severe liver pathologies, compared to histology.

KEYWORDS

Liver, Pathology, Ultrasound

INTRODUCTION

The diagnosis of liver disease can be done from recorded clinical history, physical examination, various biochemical estimations, imaging methods and histology. The imaging methods, which are radiology, isotopes and ultrasound, The imaging methods together with biochemistry and histology, plays a part in reaching a final diagnosis. It is likely that the more of these methods that are employed, the more accurate and comprehensive the diagnosis is going to be. For example, isotopes and ultrasound may suggest the diagnosis of cirrhosis but the final confirmation must be by biopsy. Radiology and isotopes may show a space-occupying lesion of the liver, but ultrasound will determine whether its contents are solid or liquid. Ultrasound is considered the most cost effective primary investigation for liver pathologies and indeed right upper abdominal problems. Imaging technologies, particularly ultrasound, are inexpensive, non-invasive, readily available, and acceptable to the patient. Non-invasive approaches for assessment of liver histology include routine laboratory tests like serum markers, liver functions test, and radiological evaluation of liver. Liver histological diagnosis based on needle biopsy determines the inflammatory activity (grading), the extent of fibrosis (staging), and other co morbidities. Individual component echoes of an organ lie as transverse streaks across the direction of interrogation. Finer textures of the liver are achieved by high frequencies, short pulse lengths and tight focusing of ultrasound beam. This factor varies with the depth so that the spot size of the final image is smallest (when resolution is best) in the focal zone of the transducer. Distortions of the sound beam are commonly produced by fibrous overlying tissue, (for-example, in cirrhosis), variation in normal tissue size and overlying tissue that ultrasound has to pass through. Hence, a liver ultrasound scan, which is non-invasive, non ionizing, cost effective and time conserving, the most sensitive screening tool for sorting out the organ involved in patients with abdominal symptoms. So this study intended to find out how ultrasound techniques assist in diagnosing different common liver pathological diseases.

MATERIAL AND METHODS

This study was performed in the Department of Pathology, Darbhanga Medical College and Hospital. 592 patients were selected from outpatient departments those who were referred for clinical suspicion of abdominal pathology. Patients were selected with prior full examination of liver and abdominal viscera. Exclusion criteria maintained with OBG scans, unavailable histopathology reports.

Informed consent was taken from all the patients those not willing to give consent were not analysed and excluded. Ultrasound of the liver was performed, both lobes of liver were evaluated, and a combined impression was derived. In addition size of liver, spleen, and portal vein was also assessed and noted. The ultrasound parameters were explained to examining radiologist prior to the procedure and findings recorded on a standard proforma. Sample size calculation is done based on sensitivity of ultrasound for detecting liver disease is 77% with confidence level of 95%, margin of error 10%, and calculated sample size N = 592.

STATISTICAL ANALYSIS

Data was entered and analyzed using SPSS windows package version 19.0. Data were expressed as numbers (percentage).

RESULTS

After analysis of all the patients 243 patients were found ultrasonically positive out of which 48% were clinically suspected remaining 52% were not (Figure 1). The patients with ultrasonically negative were 349 patients, out of 31 patients were clinically suspected (Table 1 and 2). While in detail examination of abdominal pathology the prevalence of different liver pathologies found was presented figure-2 with more hepatomegaly cases.

Table 1 : Comparison of clinical suspicion with positive ultrasound findings (n=243 cases)

Clinically suspected	117 patients (48%)
Clinically not suspected	126 patients (52%)

Table 2 : Comparison of clinical suspicion with negative ultrasound findings (n=243 cases)

Clinically suspected	31 patients (8.88%)
Clinically not suspected	318 patients (91.11%)

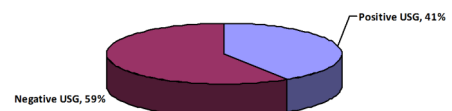


Figure : Ultrasound findings of liver pathology

Figure 1 : Analysis of total patients

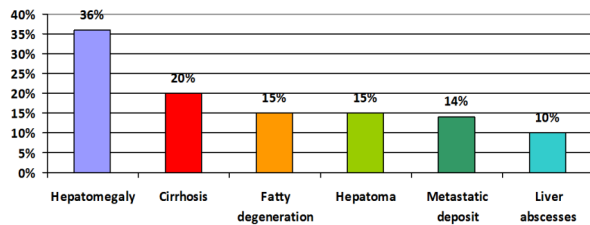


Figure :Ultrasound findings of liver pathology

DISCUSSION

Ultrasound is cheap, non-ionising, convenient, effective and user operator method. The liver readily lends itself to ultrasound imaging as it allows good transmission and reflection of sound waves and has no interposing gas shadows between it and the ultrasound probe. Also it is cheap, non-ionising, convenient and effective. Two studies stand out as having very high specificity (100% and 97.6%, respectively) and very high sensitivity (100% and 87.8%, respectively). In the diagnosis of hepatic metastatic deposits, it has been shown to have an accuracy 80%. When the differentiation of fatty liver from normal subjects was considered in a study by Foster and co-workers, the sensitivity was 60%, but these figures are misleading. These authors report false-positive rates of 5% to 14% and false-negative rates of 19% to 24%. It is clear that the values would be even higher if unknown patients had been screened. Ultrasound using real time gray scale imaging can detect a broad spectrum of hepatic pathologies including neoplasm, abscesses, fatty degeneration, cirrhosis, cysts etc. It is also useful in the pre and post operative assessment of liver transplant patients. With the advent of Doppler and colour Doppler it is comparable to angiography in its ability to show tumor blood flow. In addition, it finds ready use in portal hypertension for visualisation of collateral circulation, measurement of the portal vein, splenic vein and postoperative assessment of porto systemic shunts. Ultrasound is also used in guiding interventional procedures e.g. abscess aspiration and liver biopsies where they have been proven to be less invasive, carrying a very low risk. It is also used to guide percutaneous treatment of hepatocellular carcinoma. The potential role of ultrasound in clinical settings and in population research is very important. In the current obesity epidemic, the prevalence of fatty liver disease, in particular Non-alcoholic fatty liver disease, is likely to increase, making it necessary to use practical tools for measuring the burden of disease and tracking time trends. In the clinical context, the number of patients at risk for fatty liver disease is also increasing. There is thus a pressing need to have readily available, accurate methods to assess the presence of fatty liver, and ultrasound compares favorably to alternative noninvasive techniques. Liver enzymes, indirect markers of liver injury, have lower sensitivity (0.30-0.63) and specificity (0.38-0.63) than ultrasound.

In developing countries CT scan is not recommended as primary investigation due to greater cost and less availability but reserved for equivocal cases because there is drawback for ultrasound as it poorly differentiates diffuse diseases eg., fatty liver and cirrhosis. Another radiologic method that can be used in assessing the liver is radioisotope scanning. Its use is mainly in detecting focal lesions. Masses smaller than 2cm are usually not resolved.

CONCLUSION

The greatest value of ultrasound in the diagnosis of liver disease is to distinguish between solid tumours and fluid-containing cysts or abscesses. It is the only non-invasive diagnostic method that can do this. Ultrasound has a place in the demonstration of diffuse abnormalities but it may not distinguish the type of lesion present. In addition, it is helpful in diagnosing adjacent space-occupying lesions which displace the liver. Doppler ultrasounds are highly recommended for revealing portal hypertension and other complication of diffuse liver diseases

REFERENCES

1. Antonucci F, Stuckmann G, Burge H.R. Otho R.C. Ultrasound Guided Incisional Biopsy in generalized and focal diseases of the Liver. *Ultraschall Med* 1986; (5):203-8.
2. Broz P, Jacob AL, Fehr J, Kissel CK. An unusual presentation of amebic liver abscesses. *CMAJ: Canadian Medical Association Journal*. 2010;182(16):1755-1757.
3. Connor SEJ, Banerjee AK. General Practitioner requests for Upper Abdominal Ultrasound: their effect on clinical outcome. *The British Journal of Radiology*, 1998;71(2):1021-1025.
4. E.M. Brunt. Grading and staging the histopathological lesions of chronic hepatitis: the Knodell histology activity index and beyond. *Hepatology*. 2000;31(1):241-6.

5. Foster KJ, Dewbury KC, Griffith AH, et al. The accuracy of ultrasound in the detection of fatty infiltration of the liver. *Br J Radiol* 1979;53(2):4401.
6. Hagen Anset S. Hepatobiliary Disease: Focus on Hepatitis, cirrhosis, hepatitis, Cirrhosis, Hepatocellular Carcinoma and Liver Transplantation. Online CME Courses.
7. Irene Floriani, Valter Torri, Eliana Rulli, Daniela Garavaglia, Anna Compagnoni, Luca Salvolini, and Andrea Giovagnoni. Performance of Imaging Modalities in Diagnosis of Liver Metastases From Colorectal Cancer: A Systematic Review and Meta-analysis. *Journal of Magnetic Resonance Imaging* 2010; 31(3):19-31.
8. J Okoye, CI Eke, ASO Aderibigbe, PCN Okere, SN Ezeofor, FI Obioha. Ultrasound in diagnosis of hepatic pathologies: a review of two years experience in University of Nigeria Teaching Hospital, Enugu, Nigeria. *West African Journal of Radiology* 2005;12(1):20-25
9. J. F. Gerstenmaier and R. N. Gibson. Ultrasound in chronic liver disease. *Insights Imaging* 2014; 5(4): 441-455.
10. Neuschwander-Tetri BA, Clark JM, Bass NM, Van Natta ML, Unalp-Arida A, Tonascia J, et al. Clinical, laboratory, and histological associations in adults with nonalcoholic fatty liver disease. *Hepatology* 2010; 52(5):913-924.
11. Nicolau C, Bianchi L, Vilana R. Gray Scale Ultrasound in Hepatic Cirrhosis and Chronic Hepatitis Diagnosis, Screening and Intervention. *Semin Ultrasound CT, MR* 2002; (1): 3-18.
12. Nishiura T, Watanabe H, Ito M, Matsuoka Y, Yano K, Daikoku M, Yatsuhashi H, Dohmen K, Ishibashi H. Ultrasound evaluation of the fibrosis stage in chronic liver disease by the simultaneous use of low and high frequency probes. *British journal of radiology* 2005; 78(1): 189-197.
13. Palmer, PES et al, Tropical Diseases. in: Pettersson H (Ed.) *Radiology of Abdominal and Tropical Diseases*. The NICER Institute, Oslo; 1995:260-263.
14. Sudhakar K. Venkatesh, Vishal Chandan, Lewis R. Rober. Liver Masses: A Clinical, Radiologic, and Pathologic Perspective. *Clin Gastroenterol Hepatol*. 2014; 12(9): 1414-1429.
15. Taylor K.J.W, Ramos I., Morse S. S. et al. Focal liver masses: differential diagnosis with pulsed Doppler ultrasound. *Radiology*, 1987; 163(6):830.
16. Xu Y, Wang B, Cao H. An ultrasound scoring system for the diagnosis of liver fibrosis and cirrhosis. *Chin Med J (Engl)* 1999; 112(4): 1125-1128.