



EVALUATION OF PONSETI METHOD AS TREATMENT FOR IDIOPATHIC CLUB FOOT : AN INDIAN PERSPECTIVE.

Orthopedics

Agarwal Vipul*	Associate professor, ASMCS Firozabad. *Corresponding Author
Shakunt R K	Associate professor, S N Medical college Agra.
Dinker K S	Assistant professor, S N Medical college Agra.
Kapoor Rajat	Assistant professor, S N Medical college Agra.
Pal C P	Professor, S N Medical college, Agra.
Yadav Rohit	Senior Resident, S N Medical College, Agra.

ABSTRACT

Introduction- idiopathic congenital talipes equino-varus (club Foot) is the most common congenital foot deformity, which is very difficult to treat. Ultimate goal of treatment is to obtain a normal looking foot with normal function for all practical purposes.

Material And Methods - We have treated 125 patients with 178 idiopathic club foot deformity by serial casting using Ponseti method and followed by steenbeek foot abduction brace application. Final outcome was assessed by pirani scoring.

Results - The average number of casts that were applied to obtain correction was 6.5 (range four to nine casts). Tenotomy needed in 86 % patients. After the cast correction, treatment was found successful in 167 feet (93.6%) in which excellent result (with pirani score 0) in 94 feet, while good result in 73 feet (pirani score .5). result was found unsuccessful in 11 feet and they all were rigid in nature.

Conclusion- The Ponseti method is a gold standard treatment for congenital idiopathic clubfoot and significantly reduces the need of corrective surgery, especially in developing countries where operative facilities are very less.

KEYWORDS

idiopathic club foot, pirani score, steenbeek brace, tenotomy

INTRODUCTION

Congenital talipes equinovarus (club foot) is one of the most common congenital foot anomaly and history of disease is so old as it is described by Hippocrates in the year 400 BC⁽¹⁾. In India, in each 10 minutes a child is born with this deformity and in world 50,000 children are born with Clubfoot deformity every year⁽²⁾. Club foot is associated with various neuromuscular diseases and syndromes but idiopathic is most common type. Beauty of this idiopathic variety is that they respond very early to conservative treatment and following these conservative treatment.

The Ponseti technique, named after late Dr. Ignacio Ponseti (Spanish physician) is a most efficient technique till now for manipulation and this technique is totally based on a proper understanding of functional anatomy of the foot and on the biological response of newly developed connective tissue and bones in to corrective position which is gradually obtained by manipulation and casting⁽³⁾.

Although Ponseti method is very fruitful but the technique is very demanding (adequate deformity correction at adequate time with strict bracing protocol).

MATERIAL AND METHOD

125 cases (178feet) were treated by ponseti method between august 2013 to dec 2016. All cases were recruited from out patient department of orthopaedics, gynecology and paediatrics, S N Medical College, Agra. All the patients were treated in out patient department by manipulation and serial casting without any sedation and anaesthesia.

Ponseti Technique

Ponseti technique can be divided into two phases:

- A- First phase in which Correction of the deformity by weekly serial casting
- B- Second the maintenance phase, during which time a brace is utilized to prevent recurrence.

In first phase where deformity should be corrected by manipulation and serial casting. During the manipulation child should be relaxed by his/her mother and foot should be held in corrective position for 1-3 minutes. After the manipulation long leg cast was applied for 7 days with knee in 90 degree flexion.

Each clubfoot under Ponseti management was "scored" each week for HS (hind-foot score), MS (mid-foot score), and G (total score). Tenotomy of achilles tendon was performed, when HS < 1,

MS < 1 and calcaneum was sufficiently abducted beneath the talus. After the proper counseling of parents, procedure was done under sedation achieved by syrup pedicloryl and local anaesthesia. and the patients were discharged on the same day. post tenotomy, the last cast was applied for 3 weeks in position of dorsi-flexion and abduction. A Steenbeek brace was applied immediately after the last cast removal. Steenbeek braces for each patient were provided by a non-governmental organization (NGO) free of cost. In bilateral cases, it was set at 70° of external rotation on each side while in unilateral cases, the brace was set at 70° of external rotation on the clubfoot side, and 40° on the normal side. The bar should be bent 5–10° with the convexity away from the child, to hold the feet in dorsiflexion. The brace should be worn full-time (day and night) for the first three months after the tenotomy, then the brace should be worn for 12 hours at night and two to four hours in the middle of the day, for a total of 14–16 hours (nights and naps protocol) during each 24-hour period. In the brace, the knees are left free. Bracing was continued for up to four years of age. After applying the brace for the first time after the tenotomy, the child returns according to the following schedule.

Two weeks (to check for compliance issues)

Three months (to teach the nights-and-naps protocol)

Every four months until age three years (for compliance monitoring and check for any relapses)

Every six months until age 4 years

Every one to two years until skeletal maturity

During follow-up, the relapses, if any, were treated appropriately. Equinus required repeat tenotomy, while forefoot adduction, cavus and intoeing were all treated with repeat casting.

Each foot was evaluated cosmetically, functionally and rated according to the following criteria:

- (1) Successful (a) Excellent - in which all deformities were completely corrected (Purani score 0)
- (b) Good - in which deformities in minor degree were persistently Present (pirani score 0.5 – 1)
- (2) unsuccessful -. poor - Loss of correction and recurrence of the deformity requiring re-manipulation or repeat tenotomy soft tissue release.

OBSERVATIONS AND RESULT

Table 1. Age Of Presentation In Weeks

<4 weeks	39 (31%)
----------	----------

4-6 weeks	47 (39%)
6-8 weeks	14 (11%)
8-12 weeks	13 (10%)
12-24 weeks	4(3%)
24-36 weeks	5 (4%)
36-48 weeks	3 (2%)

Table 2. Duration Of Cast Application In Weeks

4 weeks	9 (4.8%)
5 weeks	128 (72%)
6 weeks	17 (9.6%)
7 weeks	11 (6.4%)
8 weeks	10(5.6%)
9 weeks	3 (1.6%)

Table 3. Final Outcome Of Treatment

result	rigid	non rigid (supple)	total feet
successful	69	98	167(93.6%)
excellent: (pirani score 0)	27	72	94 (52.8%)
good: (pirani score .5-1)	47	26	73 (40.8%)
unsuccessful (pirani score >1)	11	0	11 (6.4%)

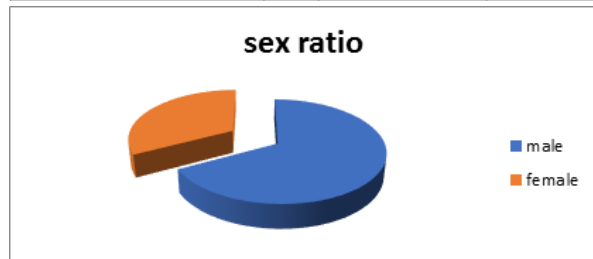


Chart No 1.

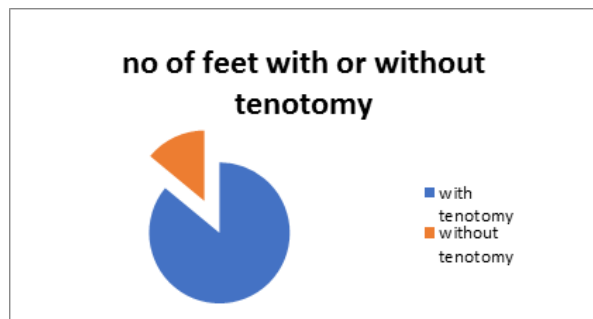


Chart No 2.

RESULT

A total of 178 feet [84 males (67%) and 41 females (33%)] in 125 children were treated by the Ponseti method and the results were assessed in the time period of august 2013 to December 2016. 53 children had bilateral clubfeet (106 feet), 71 were unilateral. We found that males are more commonly involved with club foot than females and ratio is about 2:1. Majority of cases were presented before 6 weeks (70%). The majority of cases (72.0%) required five casts to complete correction, with a mean of 6.5. The average duration of cast application was 6.5 weeks, a majority of clubfoot (72%) were treated for five weeks. Tenotomy was required in 153 (86%) feet and most of these had Pirani scores of more than 5 at the time of initiation of treatment. The average duration of follow-up was 20.8 months (range 6–40 months). After the cast correction, treatment was found successful in 167 feet (93.6%) in which excellent result (with pirani score 0) in 94 feet, while good result in 73 feet (pirani score .5). result was found unsuccessful in 11 feet and they all were rigid in nature. Later they all 11 cases were presented as relapse cases (five forefoot adduction, three equinus, two cavus, one toe inclawing) and encountered during follow-up. Equinus required repeat tenotomy, while the rest were all treated with repeat casting.

DISCUSSION

Clubfoot is a complex, congenital deformity of the foot also known as 'congenital talipes equinovarus' (CTEV) caused by abnormal position of two important tarsal bone the navicular and calcaneus and tightening of various soft tissue structures around these bones (5). It is

a very complex deformity of foot that's why it needs ultra care during manipulation and maintenance phase. When the condition is neglected, deformity causes a lifetime of disability as the affected child experiences pain and difficulty in walking. Incidence of club foot is ranging from 1–2 per thousand births. Males are affected twice as often as females and the condition is bilateral in one-third of cases(6). In our study boys were affected twice as compare to girls (m:f=2:1)

The maximum number of casts per feet in our study were ten and minimum were 4 (average 6.5) while in study by Ponseti et al. the number of cast per feet was five to ten (average 7.6). Laaveg et al. in their study reported that the mean number of casts during their treatment was seven(6). Morcuende et al. reported that 90% of the patients required five or fewer casts. The duration of casts for more than 76% of feet was five weeks or less. In our study tenotomy needed in 86% patients. Laaveg et al. did tenotomy in 78% cases(6), another study by Dobbs et al. tenotomy was required in 91% cases(7). A study by Thacker et al., sample size were 44 and all were treated with serial casting using the Ponseti technique followed by foot abduction brace (steenbeek) application. They found that the feet of patients compliant with the brace remained better corrected as compare to the feet of those patients who were not compliant(10). In our study we also used a Steenbeek foot abduction brace. After six months of treatment, time when patients were on night splints, the Pirani score had become zero that indicates successful correction of the clubfoot deformity.

The Ponseti method of conservative clubfoot treatment is most efficient method of club foot treatment, It prevents the complications of surgery and gives a painless, mobile, normal-looking, functional foot which requires no special shoes and allows fairly good mobility. Results of the clubfoot treatment by Ponseti technique in our study have been good and fruitful. In a developing country like India, where there is a lack of proper facilities in remote areas, this technique is a very effective, safe, easy, productive, and economical method of clubfoot management.

REFERENCES

1. kite JH. The club foot New York: grune and Stratton 1964
2. CURE international india 2015
3. Treatment of idiopathic clubfoot. A thirty year follow up note, cooper DM, Dietz FRJ bone joint surg Am. 1995 OCT, 77(10): 1477-89
4. Ponseti IV (1994) The treatment of congenital clubfoot. J Orthop Sports Phys Ther 20(1):1
5. Dietz F (2002) The genetics of idiopathic clubfoot. Clinical orthopaedics and related research
6. Soloman L, Warwick DJ, NavagamS, Appley's system of orthopaedics and fracture. 8th ed. London Arnold; 2001
7. Laaveg SJ, Ponseti IV (1980) Long-term results of treatment of congenital clubfoot. J Bone Joint Surg Am 62(1):23-31
8. Dobbs MB, Gordon JE, Walton T, Schoenecker P (2004) Bleeding complications following percutaneous tendoachilles tenotomy in the treatment of clubfoot deformity.
9. Morcuende JA, Abbasi D, Dolan LA, Ponseti IV (2005) Results of an accelerated Ponseti protocol for clubfoot. J Pediatr Orthop
10. Thacker MM, Scher DM, Sala DA, Van Bosse HJ, Feldman DS, Lehman WB (2005) Use of the foot abduction orthosis following ponseti casts: is it essential? J Pediatr Orthop.